



OSI

Ocular Surface Insight

Issue 18

**Cosmetics:
Time to come clean**

Eye in systemic diseases

**TFOS lifestyle: Impact of societal
challenges on the ocular surface**

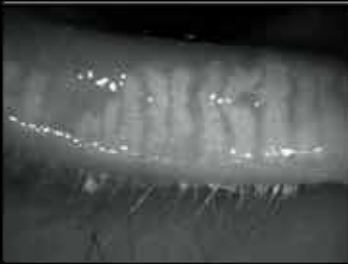DAYBREAK
MEDICAL

• ILLUMINATE •

I.P.L. TREATMENT
OF **DRY EYE**

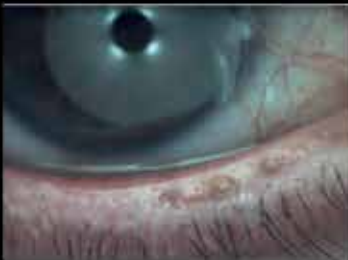1

M.G.D
Meibomian Gland Dysfunction



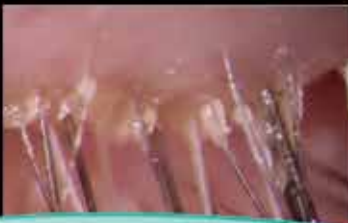2

INFLAMMATION
Rosacea and blepharitis

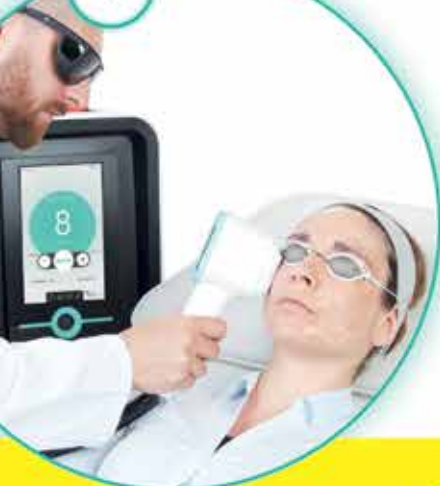

3

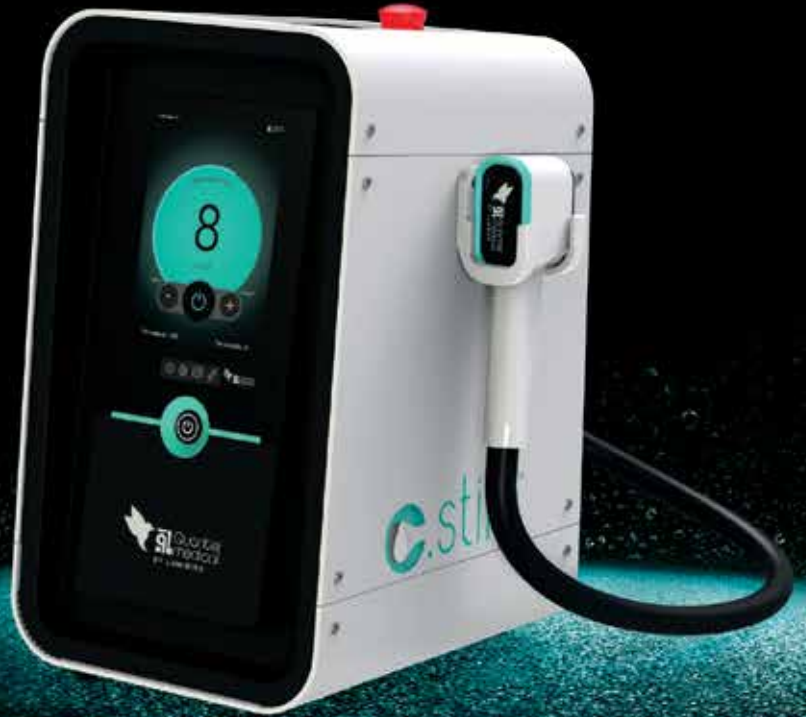DEMODEX



+



c.stim™



MULTIPLE CLINICAL RESULTS:

- Improved tear film quality
- Better meibum quality and expression
- Reduction in patient symptoms and neuropathic pain relief
- Reduced inflammatory markers in tears



LEARN MORE?

Ocular Surface Insight



“We can only see a short distance ahead, but we can see plenty there that needs to be done.”

Alan Turing

Welcome to the Spring issue of the **OSI** Magazine

Welcome to the spring edition of the Ocular Surface Insight (OSI) magazine! In this issue, we bring you articles and insights which will highlight the latest trends, and research in ocular surface health.

In section 1-2 of ‘TFOS lifestyle: Impact of societal challenges on the ocular surface’, we delve into the effects of modern lifestyles on ocular surface health, and how we mitigate these challenges to maintain healthy eyes.

We also present a fascinating study on the Effect of maqui-berry extract in dry eye disease’, by Professor Rohit Shetty and his team. This clinical and molecular analysis, provides valuable insights into potential new treatments for dry eye disease.

In addition, we feature an article on ‘Cosmetics: time to come clean’ by Jonathan Roos, Amy Gallant-Sullivan, and Rachna Murthy. This article explores the effects of cosmetics on the ocular surface, and highlights the importance of effective cleansing practices, treatments and optocosmetics to maintain healthy eyes.

We are excited to announce our webinar on the 6th of July, on the topic of Cataracts. This will explore the current trend in the UK, not to use post-surgical antibiotic prophylactically in all settings. The experts will discuss patient follow up and management of problems, particularly with complex cataract cases.

Lastly, we would like to remind our readers to save the date for the 2024 OSI Symposium & Dry Eye Master class, which will take place on the 18th & 19th of April 2024. This promises to be another successful event, where leading experts in the field will share knowledge and insights into ocular surface health. Due to the huge success of the interactive workshops, we are again increasing the number from 7 to 10, over the 2 day symposium.

We hope you enjoy this issue of OSI and find the articles informative and thought-provoking. As always, we welcome your feedback, and look forward to hearing your thoughts on this edition.

Samer Hamada

Samer Hamada,
MD, MSc, DO (hons), FRCSEd, FRCOphth

osimag.co.uk

About us

Ocular Surface Insight

Editor in Chief

Samer Hamada

Published by

VisionDuo Ltd.

Sales & Advertising

Denise Castell

denise@visionduo.com

Business Development & Marketing

Åsa Baudin

asa@visionduo.com

Conference & Educational Events

events@visionduo.com

Accounts

accounts@visionduo.com

Media No. 0001

Published May 2023

Legal Notice © VisionDuo Ltd.

None of the editorial or photographs may be reproduced without prior written permission from the publishers. Vision Duo Ltd and the Editor would like to point out that all editorial comment and articles are the responsibility of the originators and may or may not reflect the opinions of the Editor or VisionDuo Ltd. Correct at time of going to press.

This Magazine has been designed using assets from Freepik.com

If you wish to receive your own future copies of OSI magazine, please email: subscriptions@visionduo.com.

We stand with Ukraine!



VISIONDUO

Contributors



Dr. Piergiorgio Neri

MD, PhD
Staff Physician
(Retina & Uveitis)
*Eye Institute at Cleveland Clinic
Abu Dhabi, UAE*



Prof. Jonathan Roos

BA(Hons) MB BChir MA(Cantab)
PhD(Cantab) FRCOphth FEBO
Consultant Oculoplastic &
Aesthetic Surgeon
Face restoration, London



Rachna Murthy

BSc(Hons) MB BS FRCOphth
Consultant Ophthalmic,
Aesthetic, Oculoplastic &
Reconstructive Surgeon
Face restoration, London



Assoc. Prof. Anna M Roszkowska

MD, PhD, FEBO
Associate Professor of
Ophthalmology
University of Messina, Italy



Paolo Fogagnolo

University Research Scientist
in Ophthalmology
*Degli Studi University,
Milan, Italy*



Prof. Lyndon Jones

Director of the Centre for
Ocular Research & Education
*University of Waterloo,
Waterloo, Canada*



Amy Gallant-Sullivan

Executive Director & Board Member
TFOS
(Tear Film & Ocular Surface Society)
Boston, USA



Swaminathan Sethu

Scientist - Immunology at
GROW Research Lab
*Narayana Nethralaya
Foundation
Bengaluru, India*



Dr. Rohit Shetty

DNB, FRCS, PhD (Netherlands)
Consultant Cornea and
Refractive surgery
*Narayana Nethralaya Eye Institute
Bangalore, India*

Editorial Panel:

Sonia Trave-Huarte - *Editor*

Arthur Cummings - *Editor*

Prof. Rohit Shetty - *Editor*

David Lockington - *Editor*

Ankur Barua - *Editor*

Vito Romano - *Editor*

Stelios Georgoulas - *Contributing Editor*

Sundeep Kheterpal - *Article Content Editor*

Vivian Ho - *Sub Editor (Asia)*

Nathan Little - *Editor (USA Strategy & Commercial)*

Brian Tompkins - *Sub Editor Optometry*

Artemis Matsou - *Editor*

Contents


6. What's in the news?

11. Eye in systemic diseases

14. TFOS lifestyle: Impact of societal challenges
on the ocular surface

32. Cosmetics: Time to come clean

35. Effect of maqui-berry extract in dry eye disease –
A clinical and molecular analysis



What's in the news?

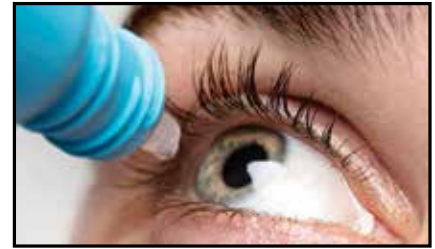Comparative evaluation of effectiveness of twenty versus fifty percent autologous serum eye drops in treatment of dry eye

The objective of the study was to compare the efficacy and safety of two concentration of autologous serum (AS) 20% vs 50% in recalcitrant moderate-to-severe dry eye patients.

A double-blind prospective, interventional, and randomized study was done on 44 patients (80 eyes) clinically diagnosed with moderate-to-severe dry eye disease (DED) that was refractory to conventional treatment, and all patients were treated with AS20% or AS50% for 12 weeks. We documented Ocular Surface Disease Index (OSDI), tear film breakup time

(TBUT), OXFORD corneal staining score (OSS), and Schirmer test (ST) at baseline, 2,4,8, and 12 weeks. These parameters were compared in both groups and between the groups by using Student's t-test. The study included 11 males and 33 females.

Out of 80 eyes, 33 eyes had moderate and 47 had severe DED. The age of patients in AS20% was 44.73 ± 14.37 years, and in AS50% was 46.41 ± 14.47 years. The most common etiology associated with DED was secondary Sjogren syndrome. In moderate DED, both the groups showed significant



improvement in both subjective and objective parameters. But in severe DED, the AS20% group failed to show any significant improvement objectively, though subjective improvement was present.

In refractory severe DED patients, AS50% is better option for treatment and in moderate DED both concentrations of autologous serum are effective.

Authors: Neha Kumari , Rakhi Kusumesh , Rekha Kumari , Bibhuti Prassan Sinha , Vivek Singh.

Publication: Indian J Ophthalmol. 2023 Apr;71(4):1603-1607.doi: 10.4103/IJO.IJO_2684_22.

Artificial intelligence to estimate the tear film breakup time and diagnose dry eye disease

The tear film breakup time (TBUT) is an important clinical indicator for diagnosing dry eye disease (DED), but its measurement requires a skilled ophthalmologist and is time-consuming. In this study, a team of Japanese researchers developed a new method that utilizes artificial intelligence (AI) to estimate TBUT and diagnose DED.

The study, published in Scientific Reports, used a dataset of 690 eyes from 345 patients, which included both healthy individuals and those with DED. The researchers developed an AI algorithm that analyzed videos of the eye to estimate TBUT by detecting the moment when the tear film breaks up. The algorithm was trained on a subset of the dataset and then tested on the remaining data to evaluate its accuracy.

The results showed that the AI algorithm accurately estimated TBUT, with a mean absolute error of 0.87 seconds. The algorithm also had a high diagnostic accuracy for DED, with a sensitivity of 91.7% and a specificity of 92.7%. The researchers compared the AI algorithm to a traditional method of measuring TBUT using fluorescein staining, and found that the AI method had similar accuracy but was much faster.

The researchers noted that their AI algorithm could be used in a clinical setting to improve the efficiency and accuracy of DED diagnosis. By automating the measurement of TBUT, ophthalmologists could save time and increase the number of patients they can see in a day. Additionally, the algorithm could be used in telemedicine settings, where patients can upload videos of their eyes for remote diagnosis.

The study has some limitations, including the fact that it only used data from

Japanese patients and that the AI algorithm has not yet been tested on a large, diverse population. However, the researchers believe that their method has the potential to revolutionize the diagnosis and treatment of DED.

In conclusion, the development of an AI algorithm to estimate TBUT and diagnose DED could have significant clinical implications. By reducing the time and expertise required for TBUT measurement, this technology could improve the efficiency and accuracy of DED diagnosis and treatment. The authors suggest that future studies could explore the use of AI in other areas of ophthalmology and healthcare.



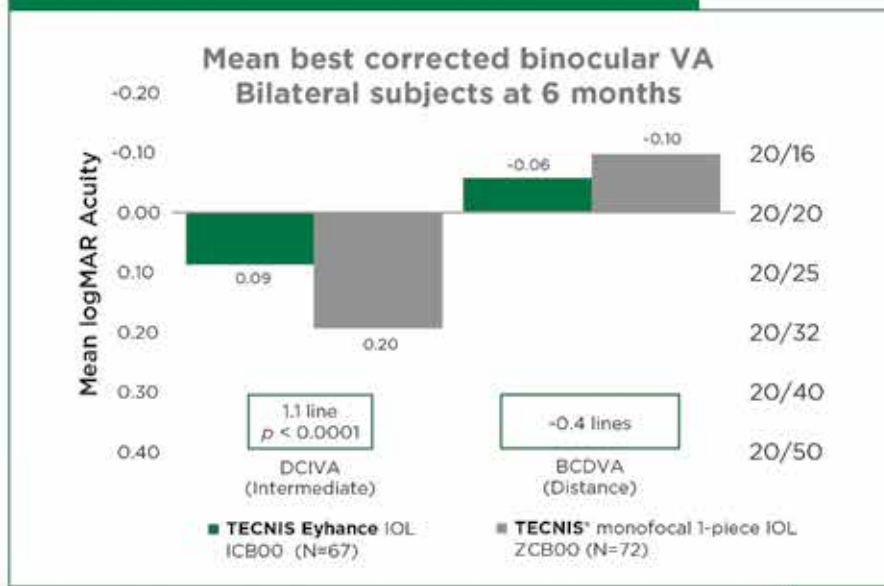
Authors: Shimizu E, Ishikawa T, Tanji M, Agata N, Nakayama S, Nakahara Y, Yokoiwa R, Sato S, Hanyuda A, Ogawa Y, Hirayama M, Tsubota K, Sato Y, Shimazaki J, Negishi K.

Publication: Sci Rep. 2023 Apr 10;13(1):5822. doi: 10.1038/s41598-023-33021-5. PMID: 37037877

TECNIS Eyhance IOL

A new generation of monofocal IOLs

Improved intermediate vision



TECNIS Eyhance IOLs (ICB00) offer a statistically significant improvement in monocular and binocular intermediate vision vs. **TECNIS**[®] monofocal 1-piece IOLs (ZCB00).¹

- Improved intermediate vision¹
- 20/20 distance vision¹

Give them more.

Enhance your patients' intermediate vision by using **TECNIS Eyhance** IOL.

Reference

1. Data on File, Johnson & Johnson Surgical Vision, Inc. Sep 2018. DOP2018CT4015.
¹Based on a clinical study, N=134 achieved mean 20/20 monocular pooled distance BCDVA.

For healthcare professionals only.

Please read the Directions for Use for Important Safety Information and consult our specialists if you have any questions.



Bring Vision to Life.

Enhanced vision within reach.

TECNIS Eyhance IOL

See the Passion in Each Patient.

Johnson & Johnson VISION

What's in the news?

Prevalence of Dry Eye Disease Among Medical Students and Its Association with Sleep Habits, Use of Electronic Devices and Caffeine Consumption: A Cross-Sectional Questionnaire

A recent study published in *Clinical Ophthalmology* examined the prevalence of dry eye disease among medical students and its association with sleep habits, electronic device use, and caffeine consumption. The cross-sectional questionnaire found that 44.9% of the medical students surveyed had dry eye disease.

The study also found a positive correlation between dry eye disease and electronic device use, as well as a negative correlation with sleep quality. The authors suggest that these findings highlight the importance of educating medical students on the impact of lifestyle factors on ocular surface health.



Authors: Alharbi A, Alharbi S, Alfawaz A, et al.
Publication: *Clin Ophthalmol.* 2021;15:3751-3760.

Efficacy and Safety of a Water-Free Topical Cyclosporine, 0.1%, Solution for the Treatment of Moderate to Severe Dry Eye Disease: The ESSENCE-2 Randomized Clinical Trial

Importance: Dry eye disease (DED) is a common public health problem with significant impact on vision-related quality of life and well-being of patients. Medications with rapid onset of action and a good tolerability profile remain an unmet need.

Objective: To assess efficacy, safety, and tolerability of a water-free cyclosporine ophthalmic solution, 0.1% (CyclASol [Novaliq GmbH]), applied twice daily in DED compared with vehicle.

Design, setting, and participants: CyclASol for the Treatment of Signs and Symptoms of Dry Eye Disease (ESSENCE-2) was a phase 3, multicenter, randomized, double-masked, vehicle-controlled clinical study conducted from December 5, 2020, to October 8, 2021. Following a 14-day run-in period with an artificial tear administered 2 times per day, eligible participants were randomly assigned 1:1 to the treatment groups. Patients with moderate to severe DED were included in the study.

Interventions: Cyclosporine solution vs vehicle administered 2 times per day for 29 days.

Main outcomes and measures:

The primary end points were changes from baseline in total corneal fluorescein staining (tCFS; 0-15 National Eye Institute scale) and in dryness score (0-100 visual analog scale) at day 29. Conjunctival staining, central corneal fluorescein staining, and tCFS responders were also assessed.

Results: A total of 834 study participants were randomly assigned to cyclosporine (423 [50.7%]) or vehicle (411 [49.3%]) groups at 27 sites. Participants had a mean (SD) age of 57.1 (15.8) years, and 609 (73.0%) were female individuals. The majority of participants self-identified in the following race categories: 79 Asian (9.5%), 108 Black (12.9%), and 635 White (76.1%). Participants treated with cyclosporine solution had greater improvement in tCFS (-4.0 grades) than the vehicle group (-3.6 grades) at day 29 (change [Δ] = -0.4; 95% CI, -0.8 to 0; $P = .03$). The dryness score showed treatment benefits from baseline in both groups: -12.2 points for cyclosporine and -13.6 points for vehicle ($\Delta = 1.4$; 95% CI, -1.8 to 4.6; $P = .38$). In the cyclosporine group, 293 participants (71.6%) achieved clinically meaningful reductions of 3 grades or higher in tCFS



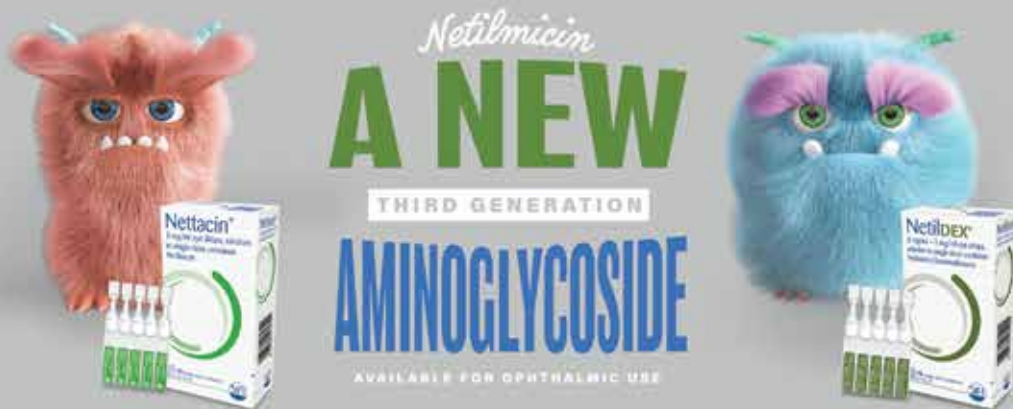vs 236 (59.7%) in the vehicle group ($\Delta = 12.6\%$; 95% CI, 6.0%-19.3%; $P < .001$). These responders showed greater improvement in symptoms at day 29 including dryness ($\Delta = -4.6$; 95% CI, -8.0 to -1.2; $P = .007$) and blurred vision ($\Delta = -3.5$; 95% CI, -6.6 to -4.0; $P = .03$) compared with nonresponders.

Conclusions and relevance:

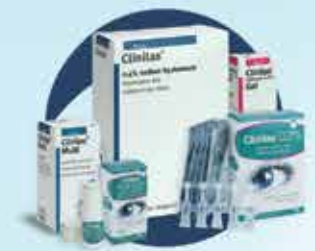The ESSENCE-2 trial confirmed that treatment with a water-free cyclosporine solution, 0.1%, results in early therapeutic effects on the ocular surface compared with vehicle. The responder analyses suggest that the effect is clinically meaningful in 71.6% of participants in the cyclosporine group.

Trial registration: ClinicalTrials.gov Identifier: NCT04523129.

Authors: Esen K Akpek, David L Wirta, Johnathon E Downing, Joseph Tauber, John D Sheppard, Joseph B Ciolino, Alice S Meides, Sonja Krösser.
Publication: *JAMA Ophthalmol.* 2023 Apr 6;e230709. doi: 10.1001/jamaophthalmol.2023.0709.



We see the world through their eyes.



INTRODUCING NETTACIN (NETILMICIN 3 MG/ML) AND NETILDEX (NETILMICIN 3 MG/ML + DEXAMETHASONE 1 MG/ML)

Third generation bactericidal aminoglycoside with proven efficacy in the topical treatment of ocular surface infections.¹⁻⁶

Preservative-free and non-cytotoxic formulation with broad spectrum activity against 95% of ocular pathogens, including multi-drug and methicillin-resistant species.¹⁻⁶

Nettacin (netilmicin 3 mg/ml) is indicated for the topical treatment of external infections of the eye and its adnexa caused by netilmicin sensitive bacteria.¹ Netildex (netilmicin 3 mg/ml + dexamethasone 1 mg/ml) is indicated for inflammatory ocular conditions of the anterior segment of the eye, including post-operative cases, where bacterial infection or a risk of bacterial infection exists.⁴ When prescribing Nettacin or Netildex, consideration should be given to official guidance on the appropriate use of antibacterial agents.²

NETILMICIN
Antibacterial sensitivity is our strength

clinitas
A VISION FOR LIFE

Netildex® (netilmicin 3mg/ml + dexamethasone 1mg/ml) eye drops Prescribing Information. Consult summary of product characteristics (SPC) before prescribing. Name and active ingredients: Netildex® (netilmicin 3mg/ml + dexamethasone 1mg/ml) eye drops. **Indication:** Treatment of inflammatory ocular conditions of the anterior segment of the eye, including post-operative cases, where bacterial infection or a risk of bacterial infection with netilmicin-susceptible microorganisms exists. Consideration should be given to official guidance on use of antibacterial agents. **Dosage and administration:** One drop four times a day in each affected eye or as prescribed. Safety and efficacy in children and adolescents less than 18 years of age not established. **Contraindications:** Hypersensitivity to active substances, aminoglycoside antibiotics or excipients. Intraocular hypertension. Herpetic keratitis or other herpes simplex ocular infections. Viral, fungal or mycobacterial ocular infections. **Special warnings and precautions for use:** Not for oral use. Should not be introduced into anterior chamber of eye. Monitor intraocular pressure if treatment lasts more than 15 days. Prolonged use may result in ocular hypertension/glaucoma. Prolonged use of corticosteroids may result in posterior subcapsular cataract formation, delayed wound healing, increased hazard of secondary ocular infections. Corticosteroids may mask

or exacerbate infection in acute purulent eye infections. Perforation has been reported with use of topical steroids in diseases causing thinning of cornea or sclera. If sensitivity to topical aminoglycosides occurs, discontinue use. Use cautiously in patients with glaucoma and carefully consider those with a family history. Co-treatment with CYP3A inhibitors is expected to increase risk of systemic side-effects. Contains phosphates which may lead to corneal deposits or corneal opacity. Use with caution in patients with compromised cornea or receiving other phosphate containing eye medications. If significant clinical improvement is not reported within a few days, or irritation or sensitization occur, discontinue treatment and start an adequate therapy. Consider referring patients with blurred vision or other visual disturbances to an ophthalmologist for evaluation of possible cataract, glaucoma or central serous chorioretinopathy (CSCR). **Interactions:** No interaction studies have been performed. Significant drug interactions have not been reported. **Fertility, Pregnancy and Lactation:** Avoid use during pregnancy. Do not use during breast feeding. **Effects on ability to drive and use machines:** May cause transient blurring of vision, patients should not drive or use machines until resolved. **Undesirable effects:** Intraocular pressure increased (after 15-20 days of topical administration in susceptible or glaucomatous patients), posterior subcapsular cataract formation,

blurred vision, occurrence or worsening of Herpes simplex or fungal infections, impaired healing, ocular hypersensitivity (conjunctival hyperaemia, burning, itching), Cushing's syndrome, adrenal suppression. Corneal calcification reported very rarely in association with phosphate containing eye drops in patients with significantly damaged corneas. **Legal Category:** POM. **Basic NHS Price:** £11.29 per pack. **Pack Size:** 20 x 0.3ml single-dose containers. **Marketing Authorisation Number:** PL53941/0009. **Marketing Authorisation Holder:** SIFI Pharmaceuticals Limited, 29/30 Fitzroy Square, London, W1T 6LQ, UK. **Further information is available from:** ParaPharm Development Ltd c/o Draupnir Holdings Ltd, Building 1410 Arlington Business Park, Theale, Reading RG7 4SA, UK. **Date of PI:** January 2022.

Adverse events should be reported. Reporting forms and information can be found at www.mhra.gov.uk/yellowcard, or search for MHRA Yellow Card in the Google Play or Apple App Store. Adverse events should also be reported to ParaPharm Development at (+44) 01183 217100 or info@parapharmdev.com

Nettacin® (netilmicin 3mg/ml + dexamethasone 1mg/ml) eye drops Prescribing Information. Consult summary of product characteristics (SPC) before prescribing. Name and active ingredients: Nettacin® (netilmicin 3mg/ml) eye drops. **Indication:** Topical treatment of external infections of the eye and its adnexa caused by netilmicin sensitive bacteria. Consideration should be given to official guidance on use of antibacterial agents. **Dosage and administration:** One to two drops three times a day in the affected eye(s) or as prescribed. Safety and efficacy in children and adolescents less than 18 years of age not established. **Contraindications:** Hypersensitivity to active substances, aminoglycoside antibiotics or excipients. **Special warnings and precautions for use:** Serious adverse reactions including neurotoxicity, ototoxicity and nephrotoxicity have occurred in patients receiving systemic aminoglycoside therapy. Caution advised when used concomitantly. Prolonged use of topical antibiotics may determine overgrowth of resistant microorganisms. If no clinical improvement reported within a relatively short period of time or irritation or sensitisation occur, discontinue therapy and start an appropriate treatment. Nettacin is not injectable, therefore it must not be injected subconjunctivally or introduced in the anterior chamber. During a superficial eye infection, use of contact lenses is strongly discouraged.

Interactions: No significant drug interactions have been reported. Concomitant administration, even topical and particularly intracavitary, of other potentially nephro- and ototoxic antibiotics may increase the risk of such effects. Concurrent or sequential use cisplatin, polymyxin B, colistin, viomycin, streptomycin, vancomycin, other aminoglycosides and some cephalosporins (cephaloridin) or potent diuretics such as ethacrynic acid and furosemide may increase the potential for nephrotoxicity; concomitant use should be avoided. *In vitro*, the association of an aminoglycoside with a beta-lactam antibiotic (penicillins or cephalosporins) may cause reciprocal inactivation. A reduction of half-life or plasma levels of aminoglycoside occurred in patients suffering from renal insufficiency and in some with normal renal activity, even if an aminoglycoside and a penicillin-like antibiotic were administered by two different routes. Patients must be informed that if more than one ophthalmic medicinal product is being used, they must be administered at least 5 minutes apart. Eye ointments should be administered last. **Fertility, Pregnancy and Lactation:** Although preclinical studies show no foetal toxicity with topical administration of netilmicin, during pregnancy the product should be administered only after a careful benefit-risk assessment and under strict medical control. Not recommended during lactation. **Effects on ability to drive and use machines:** May cause transient blurring of vision, patients

should not drive or use machines until resolved. **Undesirable effects:** Eye irritation, conjunctival hyperaemia, eyelid rash, eyelid oedema, eye pruritus, hypersensitivity and urticaria. Episodes of eye irritation and hypersensitivity caused by Nettacin are mild and transient. **Legal Category:** POM. **Basic NHS Price:** £9.83 per pack. **Pack Size:** 15 x 0.3ml single-dose containers. **Marketing Authorisation Number:** PL53941/0003. **Marketing Authorisation Holder:** SIFI Pharmaceuticals Limited, 29/30 Fitzroy Square, London, W1T 6LQ, UK. **Further information is available from:** ParaPharm Development Ltd c/o Draupnir Holdings Ltd, Building 1410 Arlington Business Park, Theale, Reading RG7 4SA, UK. **Date of PI:** January 2022.

Adverse events should be reported. Reporting forms and information can be found at www.mhra.gov.uk/yellowcard, or search for MHRA Yellow Card in the Google Play or Apple App Store. Adverse events should also be reported to ParaPharm Development at (+44) 01183 217100 or info@parapharmdev.com

References:

1. Nettacin Summary of Product Characteristics. 2. Netildex Summary of Product Characteristics. 3. Blanco A, et al. *Invest Ophthalmol Vis Sci*. 2009;50(13):2664. 4. Sanfilippo CM, et al. *Curr Eye Res*. 2016;41(5):581-589. 5. Papa V, et al. *J Cataract Refract Surg*. 2016;42:1312-1317. 6. Blanco A, et al. *Curr Eye Res*. 2013;38(8):811-816.

Date of preparation: February 2023. ALT-23-001.


ALTACOR
visionary eyecare

The Complete Dry Eye Suite

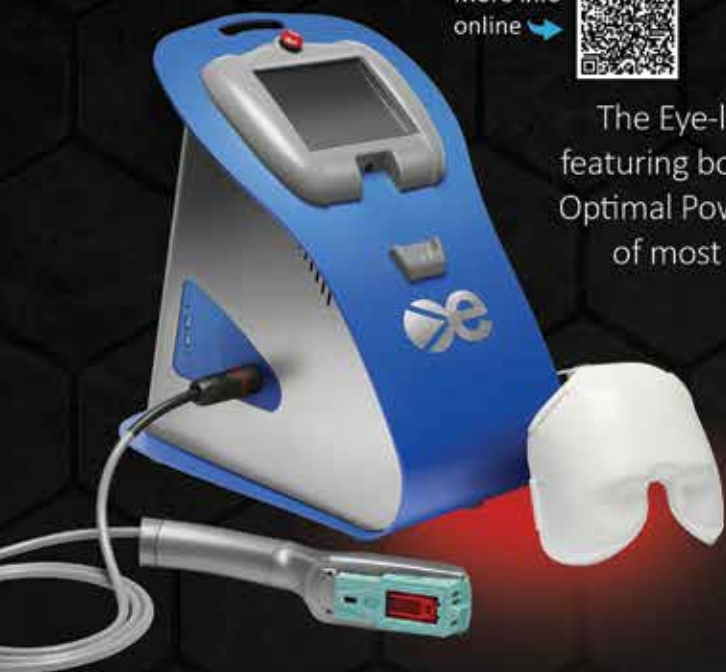Diagnose, then treat DED & MGD with the only device that can perform both IPL & LLLT

More info
online →



 eye-light®

The Eye-light® is the flagship solution from espansione group featuring both their core technologies, Light Modulation® LLLT and Optimal Power Energy® IPL, for an optimal, non-invasive treatment of most ocular surface conditions including Dry Eye Disease



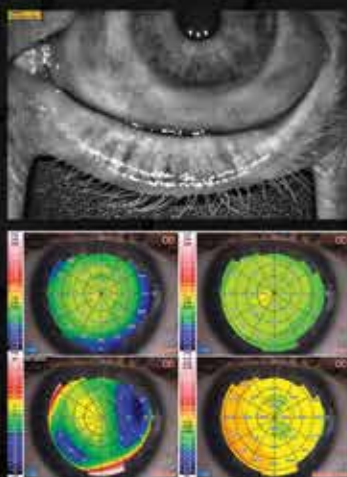
- OPE®/IPL, no gel required
- Direct treatment of meibomian glands
- The only system with non-invasive treatment of both lower and upper eyelids
- Light modulation®
- Can treat other ocular surface conditions, such as Chalazion, Sjogren's Syndrome, Stye, Blepharitis and demodex
- Option to use IPL & LLLT or LLLT only

Antares+ Corneal Topographer

With advanced analysis of the tear film and Meibomian Glands

Enables you to perform:

- Dry eye report, including:
 - OSDI Questionnaire
 - High quality imaging & video
 - Meibography
 - Tear Break up time
 - Advanced analysis of the tear film
- Keratoconus screening
- Pupilography
- Contact lens fitting module
- Will link to ortho-K lens manufacturers software



More info
online →



hanson
MEDICAL

Call: +44 (0)1527 501077

www.hansonmedical.co.uk

Eye in systemic diseases

By Anna M. Roszkowska^{1,2*},
Paolo Fogagnolo³
and Piergiorgio Neri^{4,5,6}

¹Ophthalmology Clinic, Department of Biomedical Sciences, University of Messina, Messina, Italy, ²Ophthalmology Clinic, Faculty of Medicine and Health Sciences, Andrzej Frycz Modrzewski Kraków University, Kraków, Poland, ³Ophthalmology Clinic, University of Milan, Milan, Italy, ⁴The Eye Institute, Cleveland Clinic Abu Dhabi, Abu Dhabi, United Arab Emirates, ⁵Cleveland Clinic Lerner College of Medicine, Case Western Reserve University, Cleveland, OH, United States, ⁶College of Medicine and Health Sciences, Khalifa University, Abu Dhabi, United Arab Emirates

The systemic diseases might involve the eyes in many ways, either with typical signs and symptoms or, often, with atypical presentation.

A rapid diagnosis may promote prompt treatment and a better clinical outcome in different cases.

Ocular involvement is present in metabolic, vascular, and rheumatologic diseases with retinopathy, inflammation, ocular surface, and corneal involvement. It may also be observed in different genetic syndromes. On the other hand, several systemic therapies may induce ocular changes, potentially affecting visual acuity.

This Research Topic aims to provide as comprehensive as possible information on ocular changes in systemic diseases, the signs, and symptoms that should be considered when systemic diseases are suspected. Additionally, it aims to evidence the ocular involvement in systemic disease and to highlight the necessity of the multidisciplinary approach for diagnosis and treatment.

Diabetes is undoubtedly the most common disease, with increasing prevalence worldwide, that involves different organs and tissues with diabetic angiopathy and neuropathy. It affects the eye with many degrees of severity diabetic retinopathy (DR) and cornea with tiny fibers neuropathy that affects the corneal sub-basal nerve plexus and may lead to severe visual impairment. In addition, it was reported that DR could be associated with cardiovascular involvement and stroke^(1, 2).

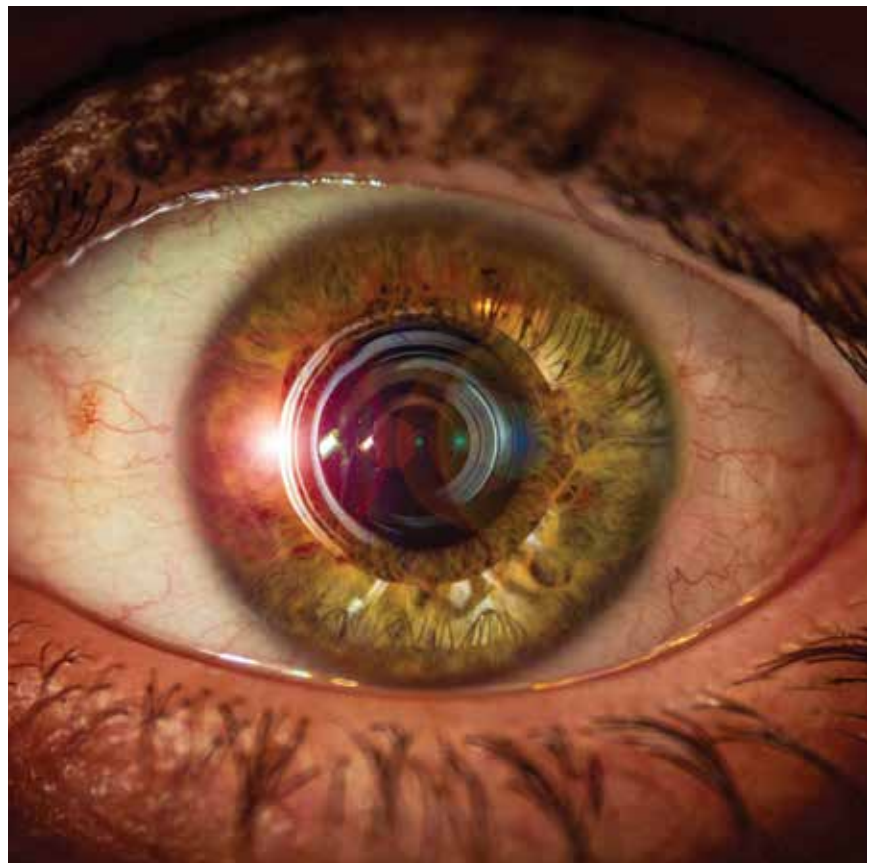
Barrot et al. evaluated the role of diabetic retinopathy as a predictor of cardiovascular morbidity and mortality in subjects with type 2 diabetes in the Catalonia (Spain) population. The authors investigated the predictive value of DR with its severity with the incidence of major cardiovascular events such as coronary heart disease, stroke, and all-cause mortality in subjects with T2DM in a Mediterranean region. They concluded that DR is related to coronary heart disease, macrovascular events, and all-cause mortality among persons

with T2DM. The authors highlighted the importance of prompt screening and proper treatment of diabetic patients with DR to avoid cardiovascular complications leading to death.

Continuing with diabetes, another paper focused on the association between serum magnesium levels and diabetic macula edema (DME) in patients with DR (Xiang et al.). The systemic conditions that result from reduced serum magnesium might worsen the DR and promote DME with severe visual impairment⁽³⁾.

brain and retina are characterized by expression of D1-like and D2-like dopamine receptors. So, the recognition of the DR as a marker of PD was hypothesized⁽⁴⁾.

Mauricio et al. evaluated the primary health care large population in Catalonia (Spain) with type 2 diabetes and diabetic retinopathy for the risk of occurrence of PD. The authors concluded that DR was not associated with an increased risk of PD after adjusting for different risk factors such as age, male sex, and diabetes duration.



The authors demonstrated that a higher serum magnesium level was associated with a lower risk of DME in patients with DR. These data open a new Research Topic to assess whether appropriate magnesium supplementation in diabetic patients reduces the risk of DME.

The relation between DR and Parkinson's disease (PD) as diabetes with DR and PD share some pathophysiological mechanisms related to stopped dopamine activity as both

Dry eye is a multifactorial ocular surface disease affecting up to 50% of the population, significantly impacting the quality of life. Several risk factors for developing the disease and sleep apnea may dramatically impact ocular surface conditions⁽⁵⁾. Pu et al. demonstrated a higher prevalence of DED in patients with obstructive sleep apnea syndrome (OSA), with a significant correlation between DED parameters worsening and OSA severity. This evident interaction should be addressed in

patients with OSA, and proper ocular surface therapy should be considered.

Severe cornea and ocular surface disease are represented by neurotrophic keratitis (NK). Several systemic diseases, such as diabetes, rheumatoid arthritis, and atopia, might produce NK with severe visual impairment. Therefore, the patients should be monitored to promptly diagnose the early stage of corneal involvement to start the appropriate therapy to avoid, if possible, the progression that may lead to visual loss⁽⁶⁻¹⁰⁾. In the paper related to NK in systemic diseases, Meduri et al. evidenced that the leading cause of NK was post-neuroma surgery (36%), followed by diabetes (18%). The remaining causes were rheumatoid arthritis (9%), post-traumatic (9%), post-surgery (9%), atopic (9%), and Graves' disease (9%). Additionally, the results of therapy with rh-NGF (Cenegermin) were presented, and the authors concluded that current knowledge of the pathogenesis of NK and the introduction of topical recombinant human Nerve Growth factor (rh-NGF) has significantly changed the natural history of the disease.

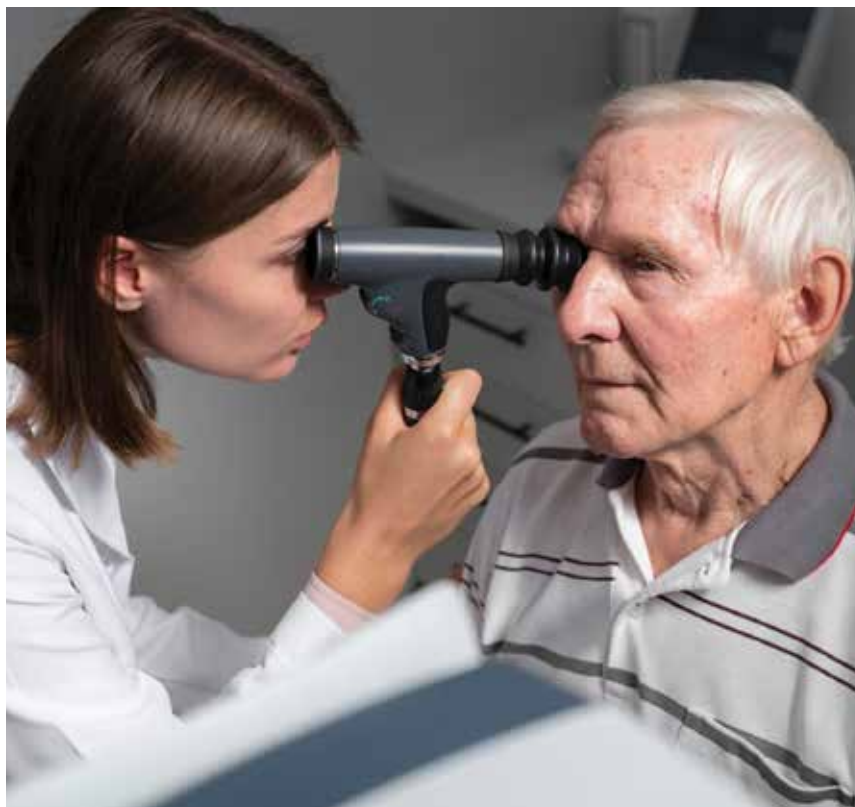The effects of smoking on the microvascular system result in ocular complications⁽¹¹⁾.

The exciting paper of Xu et al. on the impact of chronic smoking on the microvascular system demonstrated the damage to the retinal vascular system. Furthermore, the authors highlighted the role of prevention and lifestyle improvement in preventing systemic diseases.

The research and validation of the new accurate and reliable tools to be used in the screening and assessment of systemic diseases are of extraordinary actuality, primarily due to the remarkable technological progress and availability of instruments increasingly sophisticated.

Retinal changes in different neurodegenerative diseases suggest its parallel involvement with significant differences. Therefore, the retina was proposed as the window to the neurodegenerative changes in the central nervous system⁽¹²⁾.

For this purpose, Deng et al. performed a systematic review and meta-analysis to evaluate retinal and microvascular parameters in patients with PD as compared to healthy controls. The authors considered RNFL, macular, GCL, vessel density, and optic disk



area evaluated using OCT. The study evidenced that studied parameters were significantly lower in PD patients confirming that OCT and OCTA might play a role in detecting early morphological retinal changes in patients with PD and consequently support clinicians in diagnostic processes.

Additionally, OCT can classify PD patients accordingly to measure retinal changes. The authors speculated that in the next future, the OCT and OCTA might be used to assess the progression of PD based on variations of retinal parameters.

The last decades of exceptional technological progress have offered clinicians and researchers new diagnostic tools for visual disease assessment and follow-up.

And while OCT continuously improved and became essential for retinal examination, in corneal semiotics, AS-OCT and IVCM are now fundamental. Moreover, the use of IVCM to diagnose systemic diseases by corneal SBNP examination has become of growing interest, and its use in the assessment of diabetic peripheral polyneuropathy was widely documented⁽¹³⁻¹⁶⁾.

Gu et al. performed a review of corneal confocal microscopy in the assessment of non-neurological autoimmune diseases. The authors concluded that

IVCM parameters were altered in patients with NNAI affections compared to healthy subjects and highlighted the role of IVCM in early diagnosis and follow-up of affected patients.

The research to develop a more accurate analysis of IVCM data is the topic of the paper of Abicca et al., who presented the new algorithm for the evaluation of corneal nerves beadings in diabetic patients using IVCM. This new evaluation method adds a further possibility to investigate nerves changes in the early stage of peripheral neuropathy.

Lombardo et al. reports retinal imaging with new devices and a new approach to AMD.

Age-related macular degeneration is a visual threatening multifactorial disease with several systemic disorders such as hypertension, overweight, and low dietary intake of carotenoids act as decisive risk factors⁽¹⁷⁾. In their report, the authors present a new system providing topical delivery of lutein into the retina using iontophoresis and show promising results of the pilot study on patients with AMD^(18, 19). Furthermore, the authors discuss the advantage of using adaptive optics technology to improve the performance of optical systems by reducing the effects of optical distortions. Consequently, the improved resolution provides a more sensitive tool to study, detect, and track retinal diseases.

Additionally, they present Resonance Raman spectroscopy (RRS) as one of the most promising technologies for measuring macular carotenoid levels from the human retina^(20, 21).

Ocular adverse effects of systemic therapies were the topic of some papers.

The use of dupilumab, a targeted biological drug for atopic dermatitis (AD), is widely performed in adults and children. But the adverse effects could be expected, and they manifest with ocular surface diseases⁽²²⁾. Jia et al. reviewed ocular adverse effects in patients treated with dupilumab for atopic dermatitis. The AE associated with the therapy manifested in up to 50% of patients with non-infectious conjunctivitis, followed by ocular pruritus, blepharitis, xerophthalmia, and keratitis. The cause is

attributable to the inhibition of goblet cells through blocking IL-4 and IL-13 with dupilumab, which results in reduced mucin secretion. Another mechanism of conjunctivitis may be associated with serum IgE, thymus, and activation-regulated chemokine in dupilumab-treated patients⁽²³⁾. The authors reported good treatment results with fluorometholone or tacrolimus in affected patients providing dermatologists and ophthalmologists with diagnostic and therapeutic recommendations.

The widespread use of local and systemic corticosteroids might be controversial, and accurate estimation of risk and benefits should be consistently done⁽²⁴⁾. This problem emerges from the case report on the role of corticosteroids in treating acute ocular toxoplasmosis in an

immunocompetent patient⁽²⁵⁾. Lin et al. showed that the early use of systemic corticosteroids in patients with acquired ocular toxoplasmosis might induce severe retinal visual-threatening complications. Therefore, they recommend accurate and continuous visual monitoring during therapy.

In conclusion, this special issue includes papers that provide information on ocular involvement in systemic disease that should be promptly diagnosed and treated. The multidisciplinary approach to diagnose, treat, and monitor the patients is recommended. Additionally, the issue highlights new possibilities to diagnose and follow up different systemic diseases by ophthalmic evaluation using the new examination tools. We hope that the content of this special issue will raise the level of understanding how the systemic diseases might impact on ocular health.

References:

1. Guo VY, Cao B, Wu X, Lee JJW, Zee BC. Prospective association between diabetic retinopathy and cardiovascular disease—a systematic review and meta-analysis of cohort studies. *J Stroke Cerebrovasc Dis.* (2016) 25:1688–95. doi: 10.1016/j.jstrokecerebrovasdis.2016.03.009
2. Hu K, Jiang M, Zhou Q, Zeng W, Lan X, Gao Q, et al. Association of diabetic retinopathy with stroke: a systematic review and meta-analysis. *Front Neurol.* (2021) 12:626996. doi: 10.3389/fneur.2021.626996
3. Xing B, Xu X, Li C, Zhao Y, Wang Y, Zhao W. Reduced serum magnesium levels are associated with the occurrence of retinopathy in patients with type 2 diabetes mellitus: a retrospective study. *Biol Trace Elem Res.* (2021) 200:2025–32. doi: 10.1007/s12011-021-02824-w
4. Cereda E, Barichella M, Pedrolli C, Klersy C, Cassani E, Caccialanza R, et al. Diabetes and risk of Parkinson's disease: a systematic review and meta-analysis. *Diabetes Care.* (2011) 34:2614–23. doi: 10.2337/dc11-1584
5. Magno MS, Utheim TP, Snieder H, Hammond CJ, Vehof J. The relationship between dry eye and sleep quality. *Ocul Surf.* (2021) 20:13–9. doi: 10.1016/j.jtos.2020.12.009
6. Bonini S, Lambiase A, Rama P, Sinigaglia F, Allegretti M et al. Phase II randomized, double-masked, vehicle-controlled trial of recombinant human nerve growth factor for neurotrophic keratitis. *Ophthalmology.* (2018) 125:1332–43. doi: 10.1016/j.ophtha.2018.02.022
7. Saad S, Abdelmassih Y, Saad R, Guindolet D, Khoury SE, Doan S, et al. Neurotrophic keratitis: frequency, etiologies, clinical management and outcomes. *Ocul Surf.* (2020) 18:231–6. doi: 10.1016/j.jtos.2019.11.008
8. Roszkowska AM, Inferrera L, Aragona E, Romina G, Postorino EI, Aragona P. Clinical and instrumental assessment of the corneal healing in moderate and severe neurotrophic keratopathy treated with rh-NGF (Cenegegermin). *European J Ophthalmol.* (2022) 32:3402–10. doi: 10.1177/11206721221097584
9. Inferrera L, Aragona E, Wylegala A, Valastro A, Latino G, Postorino EI et al. The role of hi-tech devices in assessment of corneal healing in patients with neurotrophic keratopathy. *J Clin Med Ophthalmol.* (2022) 12:3924.
10. Fogagnolo P, Giannaccare G, Bolognesi F, Digiuni M, Tranchina L, Rossetti L et al. Direct versus indirect corneal neurotization for the treatment of neurotrophic keratopathy: a multicenter prospective comparative study. *Am J Ophthalmol.* (2020) 220:203–14. doi: 10.1016/j.ajo.2020.07.003
11. Galor A, Lee DJ. Effects of smoking on ocular health. *Curr Opin Ophthalmol.* (2011) 22:477–82. doi: 10.1097/ICU.0b013e32834bbe7a
12. Moreno-Ramos T, Benito-Leon J, Villarejo A, Bermejo-Pareja F. Retinal nerve fiber layer thinning in dementia associated with Parkinson's disease, dementia with Lewy bodies, and Alzheimer's disease. *J Alzheimers Dis.* (2013) 34:659–64. doi: 10.3233/JAD-121975
13. Patton N, Aslam T, Macgillivray T, Pattie A, Deary IJ, Dhillon B. Retinal vascular image analysis as a potential screening tool for cerebrovascular disease: a rationale based on homology between cerebral and retinal microvasculatures. *J Anat.* (2005) 206:319–48. doi: 10.1111/j.1469-7580.2005.00395.x
14. Roszkowska AM, Wylegala A, Gargiulo L, Inferrera L, Russo M, Mencucci R et al. Corneal sub-basal nerve plexus in non-diabetic small fiber polyneuropathies and the diagnostic role of in vivo corneal confocal microscopy. *J Clin Med.* (2023) 12:664. doi: 10.3390/jcm12020664
15. Cruzat A, Qazi Y, Hamrah P. In vivo confocal microscopy of corneal nerves in health and disease. *Ocul Surf.* (2017) 15:15–47. doi: 10.1016/j.jtos.2016.09.004
16. Roszkowska AM, Wylegala A, Inferrera L, Spinella R, Gargano R, Orzechowska-Wylegala B, et al. Impact of corneal parameters, refractive error and age on density and morphology of the subbasal nerve plexus fibers in healthy adults. *Sci Rep.* (2021) 11:6076. doi: 10.1038/s41598-021-85597-5
17. Roszkowska AM, Licitra C, Tumminello G, Postorino EI, Colonna MR, Aragona P. Corneal nerves in diabetes—The role of the in vivo corneal confocal microscopy of the subbasal nerve plexus in the assessment of peripheral small fiber neuropathy. *Surv Ophthalmol.* (2021) 66:493–513. doi: 10.1016/j.survophthal.2020.09.003
18. Colijn JM, Meester-Smoor M, Verzijden T, de Breuk A, Silva R, Merle BMJ, et al. Genetic risk, lifestyle, and age-related macular degeneration in europe: the EYE- RISK consortium. *Ophthalmology.* (2021) 128:1039–49. doi: 10.1016/j.ophtha.2020.11.024
19. Sousa-Martins D, Sousa S, Duarte J, Marta M, Lombardo M, Lombardo G. Lutein reaches the retina following iontophoresis application. *Invest Ophthalmol Vis Sci.* (2016) 57:106.
20. Lombardo M, Villari V, Micali N, Roy P, Sousa SH, Lombardo G. Assessment of trans-scleral iontophoresis delivery of lutein to the human retina. *J Biophotonics.* (2018) 11:201700095. doi: 10.1002/jbio.201700095
21. Lombardo M, Serrao S, Devaney N, Parravano M, Lombardo G. Adaptive optics technology for high-resolution retinal imaging. *Sensors.* (2013) 13:334–66. doi: 10.3390/s130100334
22. Bernstein PS, Yoshida MD, Katz NB, McClane RW, Gellermann W. Raman detection of macular carotenoid pigments in intact human retina. *Invest Ophthalmol Vis Sci.* (1998) 39:2003–11.
23. Akinlade B, Guttman-Yassky E, de Bruin-Weller M, Simpson EL, Blauvelt A, Cork MJ, et al. Conjunctivitis in dupilumab clinical trials. *Br J Dermatol.* (2019) 181:459–73. doi: 10.1111/bjd.18276
24. Uchida H, Kamata M, Nagata M, Fukaya S, Hayashi K, Fukuyasu A, et al. Conjunctivitis in patients with atopic dermatitis treated with dupilumab is associated with higher baseline serum levels of IgE and TARC but not clinical severity in a real-world setting. *J Am Acad Dermatol.* (2020) 82:1247–9. doi: 10.1016/j.jaad.2019.12.039
25. Oray M, Ozdal PC, Cebeci Z, Kir N, Tugal-Tutkun I. Fulminant ocular toxoplasmosis: the hazards of corticosteroid monotherapy. *Ocul Immunol Inflamm.* (2016) 24:637–46. doi: 10.3109/09273948.2015.1057599

TFOS lifestyle: Impact of societal challenges on the ocular surface

Fiona Stapleton, Juan Carlos Abad, Stefano Barabino, Anthea Burnett, Geetha Iyer, Kaevalin Lekhanont, Tianjing Li, Yang Liu, Alejandro Navas, Chukwuemeka Junior Obinwanne, Riaz Qureshi, Danial Roshandel, Afsun Sahink, Kendrick Shihl, Anna Tichenor and Lyndon Jones.

1. Introduction

1.1. Approach

This report is part of the Tear Film & Ocular Surface Society (TFOS) Workshop, entitled 'A Lifestyle Epidemic: Ocular Surface Disease,' which was undertaken to establish the direct and indirect impacts that everyday lifestyle choices and challenges have on ocular surface health. It examines societal challenges in ocular surface diseases using an adaptation of a framework used to map the relationship between the individual, their environment and their health^[1]. This approach was designed to enable interventions to be addressed at a health policy level and consequently it reflects the interplay and dependencies between the different factors. The model also recognises that certain factors can be considered to fit within one or more of the levels identified. The most recent iteration of this model considers the impact of the digital world directly and indirectly on human health^[2].

The direct impact of certain individual lifestyle factors in ocular surface diseases, including^[3], is explored in detail in the respective Reports from the TFOS Lifestyle Workshop. The Societal Challenges Report will predominantly focus on how those factors contribute to societal norms that in turn influence presentation, outcome and management of ocular surface diseases and will refer to the relevant sub-committee reports for their direct effects. For example, the Societal Challenges Report will explore the impact of the digital world on access to education of practitioners and patients, telehealth or access to services, rather than the impact of digital devices per se on the ocular surface; or the effect of climate change on determinants such as clean water or access to services, rather than the effect of climate change on the ocular surface. Each section within this report will cross reference the relevant TFOS Lifestyle Reports to minimise overlap. As for the other TFOS Lifestyle Reports, evidence is summarised in a narrative style review that, wherever possible, refers to outcomes from high-quality systematic review (Level I) evidence. The Evidence Quality Subcommittee

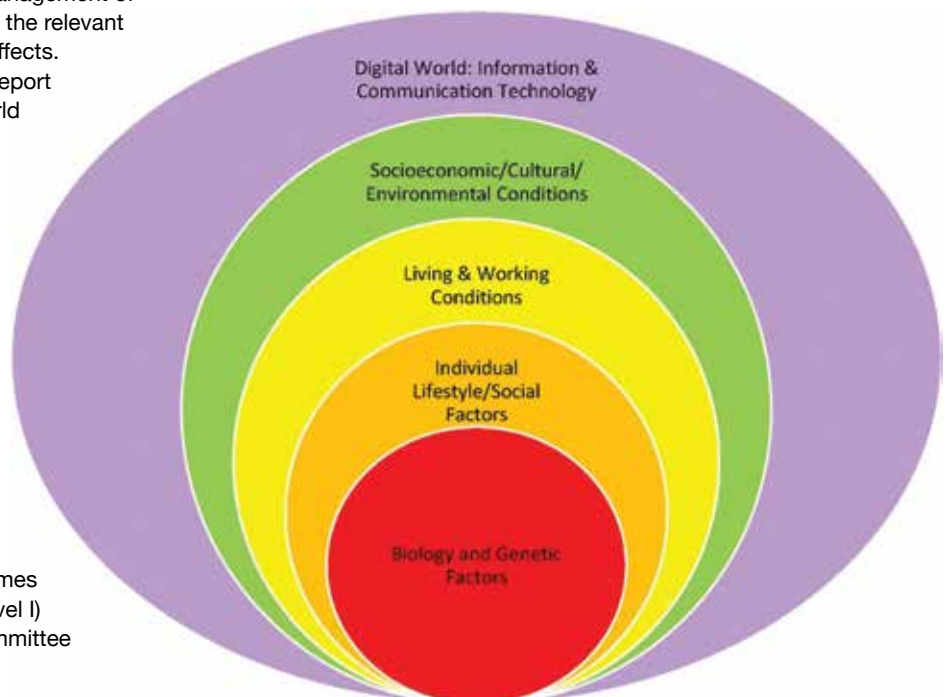
provided a comprehensive database of appraised Level 1 evidence judged to be of potential relevance, which was factored into the writing of the report^[9]. A key issue given the timing of this report was the impact of COVID-19 on the ocular surface. A systematic review to summarize the impact of the COVID-19 pandemic on the frequency and severity of ocular surface disease in both the general population and amongst those who had COVID-19, was conducted and is included in this report.

1.2. Scope

For this Workshop, the 'Ocular Surface' is defined as the cornea, limbus, conjunctiva, eyelids and eyelashes, lacrimal apparatus and tear film, along with their associated glands and muscular, vascular, lymphatic and neural support. 'Ocular Surface Disease' includes established diseases affecting any of the listed structures, as well as etiologically-related perturbations and responses associated with these diseases.

Ocular surface diseases can be acute or chronic conditions that may require long term management. For this report, conditions are considered from an etiological perspective and will broadly include trauma, infection, inflammation, allergy, neoplasia and hereditary/congenital conditions. Societal factors as described in Fig. 1 will be mapped to these etiological classifications, where possible.

Fig. 1. Framework (2019) [2]), used in this report (modified from Rice and Sara).





2. Biology and genetic factors

2.1. Age

Age-related progressive decline of physiological function affects a broad range of organs, including the eye. The degradative effects of aging may contribute to multiple ocular surface diseases.

Dry eye disease (dry eye disease) is one of the major age-related diseases of the ocular surface. Increasing age is a fairly robust risk factor for dry eye disease in population-based cross-sectional studies^[10–15], although unexpectedly high rates of disease have been reported in several studies in young adults^[16–18]. In a large study of health care records from the United States of America (USA), older adults were confirmed to be at higher risk and there was evidence of an increase in both incidence and prevalence of dry eye disease over time^[19]. Four systematic reviews and meta-analyses in a Chinese population, Japanese population, and visual display terminal workers have also supported an increase in dry eye prevalence with age^[20–23]. Conversely, there was no significant association between dry eye disease and age in one systematic review with meta-analysis in Africa, although non-population-based studies were included in this analysis^[24].

There is some evidence to suggest that the age-related association with dry eye disease is not linear and high rates of dry eye disease have been reported in children and young adults^[15,19,25–34], suggesting the relevance of other non-age-related risk factors, including sex, genetics and exogenous variables^[31,35].

The unexpectedly high rate of dry eye disease in children and young adults could be partially explained by societal or behavioural factors and lifestyle activities linked to young age. Contact lens use and high screen time were two significant risk factors among youth^[15,17,30–33]. Poor sleep quality^[33,34], allergies^[25], arthritis^[17], smoking^[28], use of oral contraceptives^[25,33], antidepressants, and anti-allergy medications^[33], ocular surgery^[33], windy conditions, very low humidity, and air-conditioning^[25] have also been associated with dry eye disease in youth. Furthermore, the younger age group (<18 years) had the highest risk of corneal surface damage in aqueous-deficient dry eye^[29]. These findings suggest that patients who have dry eye symptoms warrant early evaluation and timely intervention regardless of their age.

Age is also an established risk factor for meibomian gland dysfunction^[36,37]. The consensus that the prevalence of meibomian gland dysfunction increases with age is supported by recent population-based cross-sectional studies and a multicentre hospital-based study^[11,38,39]. A recent systematic review with meta-analysis concluded that older people are at increased risk of developing meibomian gland dysfunction^[40]. Demodex blepharitis may also increase with age as Demodex infestation on the ocular surface is more prevalent in older individuals^[41].

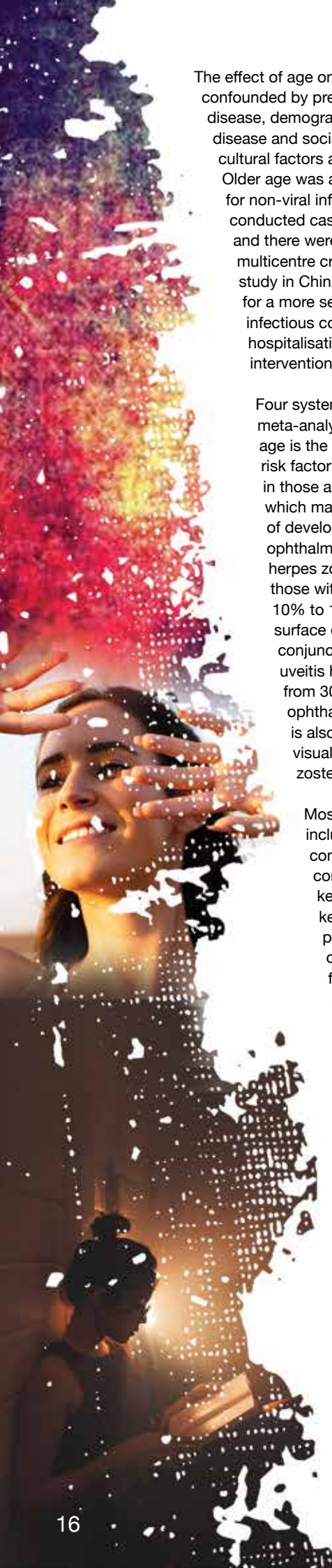Meibomian gland acinar epithelial cell atrophy, resulting in decreased lipid expression and altered meibum composition with changes in non-polar and polar lipid

profiles, may underpin the age-related effect^[36,42,43]. Histological analysis of aged human meibomian glands revealed several morphological alterations, including cystic dilatation of acini and/or ducts, atrophy of acini, thickening of the acini basement membrane, granulation tissue, and lipogranulomatous inflammation^[44]. Nevertheless, the clinical significance of such apparent changes and whether they result directly from aging or whether they are secondary to other age-related biological effects, including the changes in the levels of sex hormones and/or age-related co-morbidities are yet to be determined.

The relationship between meibomian gland dysfunction and age was not observed in African and some Asian populations^[45,46]. This may be due to a more limited age distribution in those study populations compared with others^[45,47].

Conjunctivochalasis is characterised by loose, redundant, nonedematous conjunctival folds, typically in the inferior bulbar conjunctiva interposed between the globe and the lower eyelid^[48,49]. Both the prevalence and severity of conjunctivochalasis increase with age^[48,50–53].

Pinguecula and pterygium are common ocular surface diseases affecting the bulbar conjunctiva. There is robust evidence in the literature demonstrating the effect of long-term exposure to ultraviolet light from the sun on pinguecula and pterygium^[54–57]. Four systematic reviews and meta-analyses have shown a significant positive association between age and the prevalence of pterygium^[55–58]. Two recent population-based, cross-sectional studies from China and Russia^[59,60] and one population-based, cohort study from Korea^[61], correspondingly found that older age was associated with higher risk of pterygium. A large population-based, cross-sectional study from China revealed that age is an independent risk factor for pinguecula^[54].



The effect of age on corneal infection is confounded by predisposing factors for the disease, demographic factors, systemic disease and social, environmental and cultural factors and by study design^[62]. Older age was an independent risk factor for non-viral infectious keratitis in a well conducted case control study in Uganda^[63] and there were similar findings in a large multicentre cross sectional case control study in China^[64]. Older age is a risk factor for a more severe disease outcome^[65], infectious corneal blindness^[64], hospitalisation and surgical interventions^[66].

Four systematic reviews and one meta-analysis have established that age is the most relevant independent risk factor for herpes zoster, especially in those above 50 years of age^[67-70], which may increase the likelihood of developing herpes zoster ophthalmicus^[71]. The prevalence of herpes zoster ophthalmicus among those with herpes zoster varied from 10% to 15%^[68,72]. Various ocular surface diseases, including conjunctivitis, keratitis, and anterior uveitis have been reported, ranging from 30% to 78% of herpes zoster ophthalmicus cases^[68]. Older age is also associated with severe visual loss secondary to herpes zoster ophthalmicus^[73].

Most allergic conjunctivitis, including seasonal allergic conjunctivitis, perennial allergic conjunctivitis, vernal keratoconjunctivitis, atopic keratoconjunctivitis, and giant papillary conjunctivitis, commonly presents in the first three decades of life and tend to diminish with age, although some of these diseases may persist or occur de novo in older adults^[74]. However, there is limited evidence regarding the prevalence, clinical manifestations, natural history, and management of allergic conjunctivitis in the elderly^[74-76]. Most evidence suggests that perennial allergic conjunctivitis, atopic keratoconjunctivitis and contact blepharoconjunctivitis are more frequently observed in middle-aged or older adults and are possibly associated with the use of topical ocular medications, particularly anti-glaucoma drugs, and

an impaired lacrimal function in the aged population. Changes in climate, diet, living conditions, lifestyles, air pollutants, comorbidities, and concomitant medications may impact the immune system and increase exposure to the diversity of allergens, causing changed sensitization in elderly individuals^[74,76-80].

Ocular surface squamous neoplasia is the most common non-pigmented ocular surface tumor, covering a spectrum of disease ranging from non-invasive intra-epithelial dysplasia of the conjunctiva and cornea to invasive squamous cell carcinoma^[81]. Many epidemiological studies have demonstrated that in temperate countries, aside from male sex, advanced age is an important non-modifiable risk factor for ocular surface squamous neoplasia^[81-88]. Nonetheless, ocular surface squamous neoplasia usually develops at a relatively younger age in populations in tropical climates, where human immunodeficiency virus and human papillomavirus infections are more prevalent^[89-95]. These findings have been supported by a systematic review from Africa^[96]. Two recent systematic reviews and meta-analyses have confirmed the role of human immunodeficiency and papillomavirus infections as etiologic factors in ocular surface squamous neoplasia^[97,98]. Additionally, the earlier onset of ocular surface squamous neoplasia in the tropical regions may be attributed to their proximity to the equator and consequently high levels of ultraviolet radiation^[91,99].

Conjunctival melanoma is a rare but sight and life threatening ocular surface malignancy^[100]. It is primarily a disease of middle-aged and elderly people, with the majority of patients presenting between 55 and 75 years of age, and it is seldom reported in children^[88,101-105]. A large, multicenter, population-based cohort study found that the incidence of conjunctival melanoma increased with age^[105]. Older age is also a predictor of more extensive disease and increased risk for visual acuity loss, as well as locally recurrent or new tumor formation following treatment^[104,106].

Conjunctival lymphoma, which is the third most common malignancy involving the conjunctiva, after squamous cell carcinoma and melanoma, consists mainly of 4 subtypes of B-cell non-Hodgkin lymphoma, including extranodal marginal zone lymphoma, follicular lymphoma, diffuse large B-cell lymphoma, and mantle cell lymphoma^[107,108]. Increasing age is one of the risk factors for conjunctival lymphoma and it typically presents in the seventh to eighth decades of life as a painless salmon-pink patch^[107,108]. Age older than 60 years is likewise predictive of a poor outcome for extranodal marginal zone lymphoma^[107].

In summary, age is a significant risk factor for many ocular surface diseases, including dry eye disease, meibomian gland dysfunction, blepharitis, conjunctivochalasis, pinguecula, pterygium, infectious keratitis and ocular surface tumors. With an increase in longevity and the rapidly growing number of older populations, it is expected that these ocular surface diseases will result in significant social and economic cost. Research focused specifically on better understanding, preventing and treating age-related ocular surface conditions is required.

2.2. Sex

Both sex and gender impact the prevalence of, severity of, access to and use of care and seeking care for a range of ocular surface diseases^[109]. Sex-related effects include those related to chromosomes, that is, the presence of two X chromosomes (female) with different degrees of mosaicism

and one X and one Y chromosome (male); sex hormones and the interplay with hypothalamic-pituitary hormones, thyroid, glucocorticoid hormones and others; epigenetics modulated by microRNA, DNA methylation and acetylation and environmental factors. Taken together, these factors may contribute to sex-related differences in the prevalence and clinical course of ocular surface diseases. Gender refers to self-identification and representation based on social and environmental experience [109,110]. The effects of gender are discussed in Section 5.5.

Sex-related biological and physiological differences have been identified in all ocular surface structures, including the cornea, conjunctiva, lacrimal gland, meibomian glands, tear film and in immune function which may be modulated by sex hormones. This may suggest a greater sex-related impact, particularly on those conditions related to inflammatory or immune related mechanisms [109]. Females are more susceptible than males to a range of ocular and systemic autoimmune diseases, including systemic lupus erythematosus, multiple sclerosis, rheumatoid arthritis and Hashimoto's thyroiditis [111].

Most population studies of adult dry eye disease (including both Sjögren and non-Sjögren disease) show females as having twice the risk of men in studies where the disease definition is based on dry eye symptoms, signs and symptoms of dry eye disease or a prior diagnosis of dry eye disease [10,15]. There is some evidence to suggest that the differences in certain dry eye signs, for example tear film break-up time, between the sexes reduces with age [10,112-114]. Similar to findings in adults, most evidence suggests that young females are more affected than young males [23,28,33], although significant sex differences were not apparent in two studies from Asia [31,34].

There are conceivably sex-related differences in the perception and reporting of pain and pain tolerance [115] which may influence the report of ocular surface and dry eye symptoms, although this is a complex area and there is considerable confounding in published studies, for example between chronic pain and depression and gender differences in reporting depression or seeking care (see Section 5.5). Women are more likely than men to experience chronic pain syndromes, such as fibromyalgia [15], and report more severe, more frequent and more widespread body pain [116,117].

There is a higher rate of asymptomatic meibomian gland dysfunction in Caucasian males [39]. In population-based studies from Japan and in Singapore Malays, males had a higher risk of meibomian gland dysfunction compared with females [11,46]. A higher unadjusted prevalence of meibomian gland dysfunction was reported in males in a population-based study of adults in Iran, although this effect did not persist in multivariable analysis [47]. No sex-related differences were observed in a study in an older (65 years and above) Japanese population [118], however a population study in Iran in those 60 years and over, reported a higher prevalence of meibomian gland dysfunction in men [119]. A recent systematic review and meta-analysis of population-based and hospital-based studies demonstrated male sex as an independent risk factor for meibomian gland dysfunction [40], however a meta-analysis of hospital-based studies in Africa suggested no effect of sex on meibomian gland dysfunction [45], although the age of patients in the African studies tended to be lower. There are challenges in the diagnosis and reporting of meibomian gland dysfunction; most studies have used symptoms plus the presence of either telangiectasia, lid abnormalities,

altered meibum expressibility or meibum quality, in at least one eye. It is recognized that telangiectasia is not a unique sign of meibomian gland dysfunction, and most studies do not report the proportion of participants with telangiectasia alone. Given the strong association between symptomatic dry eye disease and female sex and the understanding that evaporative dry eye disease, often due to meibomian gland dysfunction, is a major contributor to the overall disease load in symptomatic dry eye disease, the finding of either no effect of sex or a higher rate of meibomian gland dysfunction in males is perhaps unexpected. Future appropriately-powered studies should apply clear diagnostic criteria for meibomian gland dysfunction, perform analyses disaggregated by age and sex and include younger age groups.

In corneal transplantation, male grafts tend to last longer [120], whereas females function as better graft recipients [120,121]. Males have higher conjunctival goblet cell density [122] and resistance to infection and females have more superior limbic keratoconjunctivitis [123]. Women are more prone to primary acquired nasolacrimal duct obstruction [124]. Pterygium is more common among men, most likely due to occupational exposures [56].

Despite males having a higher risk of corneal infection due to trauma and contact lens wear, females had a higher risk of corneal infection in a large study from South India [65]. In a large case control study in China, sex was not an independent risk factor for infectious keratitis, however there was a higher prevalence of corneal blindness in females [57]. One study has shown that females tend to take longer to re-epithelialize following a fungal ulcer [125].

In summary, there are sex-related differences in a number of ocular surface diseases. In population-based studies, inflammatory or immune related ocular surface diseases appear to be more common in females. Despite the strong association with female sex and dry eye disease, there is no evidence, however, for a higher risk of meibomian gland dysfunction in females. There is robust evidence for males having a higher risk of ocular surface squamous neoplasia compared with females, after controlling for age and ultraviolet light exposure. For several other conditions, sex-related predisposition is more equivocal. Studies may be underpowered to explore sex as an independent risk factor, there may be confounding due to other social or gender constructs, including access to health care, employment, poverty and education.

2.3. Demographic population group

Variations in population group demographics have been reported using self-report of race, ethnicity or ancestral history. The criteria for human classification may differ between studies. These terms may be used to describe both biological or genetic variations and social constructs [126], however, the term 'race', does not have an inherent biological meaning. This report will use the terminology reported in the literature, acknowledging those limitations.

There are clear differences in the prevalence of dry eye disease with self-reported ethnicity. South-east Asians, particularly, appear to have 1.5-2x the risk of dry eye disease and meibomian gland dysfunction compared with Caucasians in studies of similar diagnostic inclusion criteria and population-based design [10,127]. In a cross sectional study of dry eye signs and symptoms amongst a co-located migrant population in New Zealand, East Asian participants reported more dry eye symptomatology and had poorer tear film



stability, lipid layer thickness and more meibomian gland abnormalities compared with Caucasian participants [128].

While there are clear regional differences in the incidence of fungal keratitis and infectious keratitis more broadly, the impact of ethnicity has not been clearly articulated, as differences between population groups have been attributed to climate, social, environmental and occupational risk factors [129]. Ethnicity has been identified as a risk factor in Indigenous compared with non-Indigenous individuals in Brazil [130,131], however a systematic review and meta-analysis has identified outdoor occupations and living in rural environments as independent risk factors rather than ethnicity [56]. Similarly, the rates of trachoma [132,133] and onchocerciasis [133], are significantly higher in Indigenous compared with non-Indigenous populations. Pterygium is more common in certain ethnic groups and in a multiethnic study in Asia, Malays had a higher risk of pterygium than Indian or Chinese participants, when controlling for other risk factors [134]. Addressing other societal confounding factors is important in the design and analysis of epidemiological studies to interrogate ethnicity as a risk factor in ocular surface diseases.

2.4. Genetics and hereditary factors

The pathogenesis of ocular surface diseases likely involves complex interactions between genes and the environment. However, little is generally known about the genetic factors involved in the susceptibility to the different diseases. Heritability in dry eye disease was explored in a twin cohort of middle aged and elderly British women [35]. There is moderate heritability of approximately 30% for dry eye disease symptoms and 40% for report of a prior diagnosis of dry eye disease by a clinician, and a varying heritability of 25%–80% for the various dry eye disease signs. Interestingly, tear break-up time showed no evidence of genetic effects.

There are a limited number of studies exploring the most common gene variants such as single nucleotide polymorphisms. A Korean study [135] extracted genomic DNA from blood samples of 251 unrelated non-Sjögren dry eye patients and 109 healthy control individuals and demonstrated significant changes among the polymorphisms, rs1143634 (F105F) in exon 5 of IL1B, and for the IL6R gene, the genotypic and allelic distribution of rs8192284, concluding that at least in Korean non-Sjögren dry eye patients, alterations in proinflammatory cytokine genes may play a pathogenic role.

The association between polymorphism of the estrogen receptor gene and dry eye disease in Chinese postmenopausal women has been explored in a Korean population [136]. The Xba I and Pvu II polymorphism of the estrogen receptor gene were studied by polymerase chain reaction-restriction fragment length polymorphism in 65 postmenopausal women with dry eye disease and 73 without dry eye disease. There was a significant difference of Pvu II polymorphism of the gene between the dry eye disease and controls in postmenopausal women, but no significant difference was found in the Xba I polymorphism. There was no report of dry eye disease phenotype in this Korean study, however. A study in Caucasians showed no association of the estrogen receptor gene polymorphism with either aqueous-deficient dry eye or evaporative dry eye [137], but the same authors showed an association between MUC1 polymorphisms and both aqueous-deficient dry eye and evaporative dry eye [138].

A retrospective cohort study in soldiers from the USA aged 21–40 [139], evaluated expression of thrombospondin 1 and its association with both post-surgical inflammation and dry eye disease one year post-PRK or LASIK. The association between refractive surgery and dry eye disease is well known, but the extent to which genetic factors may contribute has not been adequately investigated. Conjunctival impression cytology samples collected from participants were used to harvest DNA before the surgery and ribonucleic acid after surgery for gene expression analysis using reverse transcriptase polymerase chain reaction [139]. In this cohort study, patients with dry eye were 2.8x more likely to carry the single nucleotide polymorphism 1 minor allele of the thrombospondin 1 gene. This gene was also correlated with a significant decrease in TSP1 expression in the conjunctival epithelium, along with a concomitant significant increase in the expression of IL-1 β , an inflammatory marker associated with dry eye disease [139]. Although this study investigated dry eye disease only in refractive surgery patients, it is nevertheless interesting to note the report of a genetic predisposition to dry eye. The association between single nucleotide polymorphism 1 minor allele of the thrombospondin 1 gene and dry eye disease was not perfect, supporting current understanding that dry eye disease is a multifactorial condition.

The pathogenesis of Sjögren syndrome likely involves complex interactions between genes and the environment. While the candidate gene approach has been used previously to identify several genes associated with disease, two recent large-scale genome-wide association studies, reviewed by Ref. [140], have implicated many more loci as genetic risk factors. Of relevance, was the significant association of Sjögren syndrome with additional immune-related genes including IL12A, BLK, and CXCR5. Other loci and suggestive



gene associations in Sjögren syndrome were revealed, but none relating to genes encoding salivary or lacrimal components, secretion machinery or neuronal proteins involved in innervation of the glands ^[140].

Allergic eye disease affects a wide range of people of all ages and has varying degrees of severity and clinical manifestation. Allergens (pollen, ragweed, trees, and animal dander) are antigens that cause a response of the ocular surface in susceptible or atopic individuals. Atopic conditions frequently occur within families, which has been attributed to both genetic and environmental factors ^[141]. There is a strong hereditary predisposition for acute allergic conjunctivitis, although the rate of transmission is somewhat less for vernal keratoconjunctivitis. Genetic factors may influence several mechanisms involved in the pathogenesis of vernal keratoconjunctivitis, such as increased presence of eosinophils along with CD4 cells in blood, tears, and conjunctival scrapings and expression of different cytokines; however, genetics in vernal keratoconjunctivitis is mostly undefined ^[142]. It has been hypothesized that up-regulation of the cytokine gene cluster on chromosome 5q may be relevant, considering the increased accumulation of eosinophils, expression of a multitude of mediators and cytokines (IL-3, IL-4, IL-5, and granulocyte/macrophage colony stimulating factor) ^[142].

Atopic keratoconjunctivitis is almost exclusively associated with atopic dermatitis, with both genetic and environmental causes ^[143]. While ocular allergic diseases clearly have a strong hereditary component, the evidence shows that the inheritance of these diseases does not follow a classical Mendelian pattern, suggesting that the genetics of ocular allergic disease are complex and multifactorial.

2.5. Co-morbidities

Chronic co-morbid conditions influence the prevalence and severity of ocular surface diseases, particularly those conditions which alter immune function, such as chronic renal failure, diabetes mellitus, malnutrition, human immunodeficiency virus status, chemotherapy, hypertension, autoimmune disease and alcohol abuse. Conceivably, there are shared genetic associations between co-morbid conditions with certain ocular surface diseases. Many of these factors are covered in depth in the TFOS Lifestyle Impacts ^[6], Nutrition ^[3] and Elective Medications ^[144] Reports, therefore are described here only in brief, to expose their interdependencies with other societal factors.

Population and case-based studies conducted across different countries, ethnicities and environments have shown clear links between comorbid diseases and either the risk of dry eye disease or the risk of more severe disease. In the Beaver Dam Offspring Study, a populationbased study of 3275 young adults in the USA, common conditions associated with dry eye disease included allergies,

arthritis and thyroid disease ^[17]. Similarly, a population-based study in Korea examined 16, 408 adults and showed that dyslipidaemia, degenerative arthritis, rheumatoid arthritis, thyroid disease and renal failure were associated with significantly higher prevalence of dry eye disease ^[145]. A case-control study in Taiwan compared 12,007 participants with dry eye disease with 36,021 controls, and showed ischemic heart disease, hyperlipidemia, cardiac arrhythmias, peripheral vascular disease, stroke, migraines, myasthenia gravis, rheumatoid arthritis, systemic lupus erythematosus, asthma, pulmonary circulation disorders, diabetes, hypothyroidism, liver disease, peptic ulcer, hepatitis B carrier status, deficiency anemias, depression, psychoses and cancers were more common in the dry eye disease group ^[146].

In a large population-based cohort of 79,606 adult patients in the Netherlands, investigators examined medication classes and individual drugs and their association with dry eye disease, using a hypothesis-free approach ^[147]. Proton pump inhibitors, anticholinergic drugs and topical anti-glaucoma medications were independently associated with dry eye symptoms.

The Dry Eye Assessment and Management study, was a prospective randomized placebo-controlled trial examining the effectiveness of oral omega-3 supplementation in the treatment of dry eye disease ^[148]. Using the same cohort of 535 primarily Caucasian female participants, investigators identified systemic conditions associated with worse dry eye symptoms at baseline ^[149], including Sjögren syndrome, acne rosacea, rheumatoid arthritis, and peripheral vascular disease. While the relationship between certain co-morbidities and dry eye disease may have an obvious biological rationale, for example Sjögren syndrome results in lymphocytic infiltration of the lacrimal glands ^[150], directly causing keratoconjunctivitis sicca, or dermatological or sebaceous gland diseases showing associations with meibomian gland dysfunction and posterior blepharitis ^[151], other robust associations are less easily explained, for example, that between dry eye disease and peripheral vascular disease.

Co-morbidities associated with more severe dry eye disease have been explored in a Spanish Sjögren syndrome registry study of 437 patients, where inflammatory articular involvement predicted more severe dry eye disease ^[152]. Using the Netherlands Lifeline Cohort, co-morbidities associated with more severe dry eye disease among the 78,165 population-based participants included irritable bowel syndrome, fibromyalgia, chronic fatigue syndrome, eye surgery, keratoconus, osteoarthritis, connective tissue diseases, atherosclerosis, Graves' disease, autistic disorder, depression, 'burnout', Crohn's disease, sarcoid, lichen planus, rosacea, liver cirrhosis, sleep apnea and sinusitis ^[15].

Importantly, this study identified several chronic pain syndromes, namely fibromyalgia, chronic fatigue syndrome and irritable bowel syndrome, and neuropsychiatric diseases that worsened dry eye disease

^[15]. Patients suffering from chronic pain syndrome are more likely to have depression and anxiety, and as a result may take up a more withdrawn societal role ^[153]. Sufferers have negative perceptions of their interactions with care providers and conceivably these patients may have more difficulty seeking treatment for dry eye disease or other ocular surface diseases ^[153].

The association between neuropsychiatric diseases and more severe dry eye disease has been supported by other studies, with varying degrees of evidence. In a survey of 100 optometrists and ophthalmologists in North Carolina, USA, the most common comorbidities in dry eye disease patients were rheumatoid arthritis, Sjögren syndrome, affective disorders such as anxiety and depression, history of photorefractive surgery, smoking, and thyroid disease ^[154]. A significantly increased risk of dry eye disease was present in USA military veterans suffering from post-traumatic stress disorder and depression using data from a large case control study of over two million patients at a Veteran Affairs eye clinic ^[155]. This was further confirmed by a study from the same authors in 248 male USA military veterans, aged 50 and above, suffering from post-traumatic stress disorder ^[156]. Using multivariable logistic regression, both a diagnosis of post-traumatic stress disorder and use of selective serotonin reuptake inhibitors significantly increased the risk of more severe dry eye symptoms ^[156]. Clearly though, the pathogenesis of dry eye disease in such patients is complex and beyond the pharmacological side-effects alone. A possible approach is to investigate the societal context in which neuropsychiatric patients live, to identify known or new lifestyle risk factors for dry eye disease.

The impact of systemic comorbidities on ocular surface diseases were examined in 449 Japanese patients with dry eye disease at 10 eye clinics in Japan ^[157]. The most common comorbidities in this elderly cohort (mean age of 62.6 years) were hypertension, depression, and insomnia, together accounting for more than 40% of concurrent conditions. Patients with dry eye disease and systemic comorbidities had significantly worse ocular surface disease and health-related utility than those without comorbidities. Furthermore, certain comorbidities were associated with specific types of ocular surface diseases. For example, patients with insomnia and depression had higher prevalence of friction-related ocular surface diseases, which included conjunctivochalasis, superior limbic keratoconjunctivitis and lid-wiper epitheliopathy ^[157]. This may suggest specific bedtime behavioral patterns in patients with insomnia and depression that conceivably predispose to repeated ocular surface rubbing.

While the impact of comorbidities on ocular surface disease is important, it is also vital to recognize the impact of long-standing dry eye disease on mental and physical wellbeing. In the Lifeline Cohort, investigators examined the relationship between dry eye disease and quality of life in 78,165 participants ^[158]. Significantly, the study found that dry eye disease was associated with lower mental and physical health-related quality of life. Increasing dry eye disease severity was associated with decreasing health-related quality of life. Furthermore, those with undiagnosed dry eye disease had significantly worse mental health-related quality of life than those who already had a

diagnosis. Using the same cohort, investigators examined the relationship between dry eye disease and poor sleep quality ^[159]. Dry eye disease patients had higher prevalence of poor sleep quality compared to controls. Correcting for all comorbidities, dry eye disease was still significantly associated with poor sleep quality. Almost half of the participants who reported dry eye symptoms 'often' or 'constantly', had poor sleep quality. Similar findings of more severe dry eye disease and insomnia or poor sleep quality were reported in 187 USA veterans ^[160] and in a Chinese community study of 3070 participants ^[161].

In a prospective interventional case series on 45 adult patients who were receiving dry eye treatment in the USA, an improvement in dry eye severity resulted in reduction in anxiety and depression symptoms ^[162]. This was consistent regardless of whether the patient had an existing diagnosis of generalized anxiety disorder or major depressive disorder. A study using data from the Fifth Korea NHANE survey on 16,408 participants, confirmed an association between dry eye disease and increased odds of depressive symptoms and suicidal ideation ^[163].

Systemic co-morbidities, anxiety and depression and medication use are frequently associated with dry eye disease and with increased severity of dry eye disease (see also TFOS Lifestyle ^[6] and Elective Medications ^[144] Reports). There is considerable complexity as dry eye disease is associated with reduced societal participation and impact on daily activities, which may predispose to other systemic conditions. Conversely, persistent ocular discomfort may cause patients with dry eye disease to become less physically active, lose their ability to work and experience societal withdrawal. This in turn may predispose affected patients to chronic physical and mental health conditions.

The effect of co-morbidities in non-viral infectious keratitis has not been systematically explored in appropriately powered populationbased studies, although there is evidence for certain conditions to be associated with more severe infections or infectious corneal blindness. Risk factors for infectious keratitis include diabetes ^[63], alcohol ^[63] or recreational drug use ^[64]. Alcohol use is an independent risk factor for infectious corneal blindness ^[64] and rheumatoid arthritis for severe infectious keratitis ^[66]. Systemic risk factors for contact lens related infectious keratitis include diabetes as a probable risk factor and there is some evidence for associations with thyroid eye disease and self-reported poor health ^[164]. Herpes simplex virus keratitis and more severe herpes simplex virus disease are associated with diabetes ^[165, 166], although a similar association has not been shown with Herpes zoster keratitis ^[166], nor with human immunodeficiency virus status ^[165, 167].

3. Individual lifestyle/social or community factors, including nutrition, smoking, exercise

3.1. Nutrition

Eating behaviour and nutritional status play important roles in ocular surface health and disease ^[168, 169]. Societal factors are crucial determinants of adequate nutritional intake and healthy eating pattern ^[170, 171]. The 'double burden of malnutrition', referring to undernutrition on one side and being overweight and obesity on the other side, was introduced into the literature at the beginning of the 21st century ^[172, 173]. The rate of the double burden of

malnutrition has increased over the past decades, and this increase was accelerated during the coronavirus disease 2019 (COVID-19) pandemic [174,175]. Ocular surface signs of nutritional disorders and the underlying mechanisms have been reviewed in detail in the TFOS Nutrition Report [9]. In this section, societal challenges with potential ocular surface consequences through nutritional or eating imbalances are reviewed.

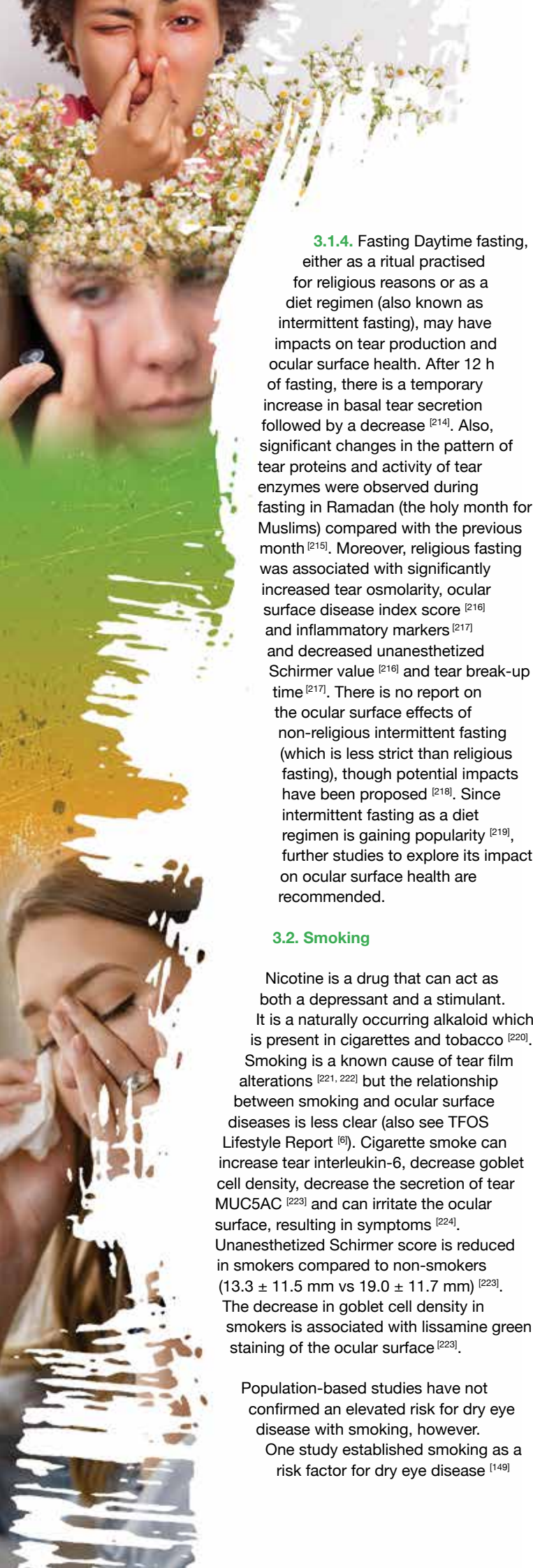
3.1.1. Food insecurity Food insecurity is understood as not having access to sufficient food, or food of an adequate quality, to meet one's basic needs. It is associated with multiple nutritional deficiencies with known ocular surface consequences [176,177]. However, the relationship between food insecurity and ocular surface disorders has been infrequently studied. Several longstanding and emerging global and regional societal challenges threaten food security. Poverty is a well-known cause of food insecurity, not only in developing countries [178,179], but also in certain groups in high-income countries [180,181]. Climate change is an emerging challenge that may impose direct and indirect impact on food security.

Extreme weather conditions result in increased poverty and reduced food consumption [182], and conversely, climate policies may impose a financial burden on developing countries through increased food and energy prices [183]. The emergence of the COVID-19 pandemic raised concerns for the exacerbation of poverty and food insecurity [184–186]. Unemployment, stay-at-home orders, and distribution shortages are potential causes of both short and long-term impacts of the COVID-19 pandemic on food security, which have a greater impact in low- and middle-income countries [187,188]. Mass immigration due to environmental, economic and security crises, remains a global challenge. Food insecurity is a common health problem among immigrants, especially among undocumented immigrants and those seeking asylum [189–191]. Immigration has been associated with lower nutritional quality for multiple nutrients, including vitamins and minerals [192,193]. However, there is a lack of evidence regarding the impact on food insecurity specifically on the prevalence or severity of ocular surface diseases among immigrants and refugees (see Section 5.8).

3.1.2. Eating disorders Anorexia nervosa is a psychological disorder characterized by fear of gaining weight, loss of appetite, and distorted body image. The incidence and lifetime prevalence of anorexia nervosa is 8/100,000 and 0.5%–2%, respectively [194,195], with a remarkable increase among young females over the past two decades [196]. Of note, there have been reports of increased risk of episodes of eating disorders during the COVID-19 pandemic, possibly due to changes in living conditions, social distancing, self-isolation, changes in food access, more intense use of social media, and more limited access to healthcare services [197–199]. There are no systematic reviews or meta-analyses on the ocular surface manifestations of eating disorders and their reversibility. A population-based study in the Netherlands with almost 80,000 participants, found eating disorders to be associated with a 1.6x increased prevalence of dry eye disease, after correction for age and sex. However, after correction for an additional 48 comorbidities, this increased risk was no longer significant [15]. Various ocular surface complications with different underlying mechanisms have been reported including a lower spontaneous blink rate during fixation tasks in patients with anorexia nervosa compared with healthy controls, which has been attributed to reduced dopaminergic activity [200]. In addition, incomplete

eye closure due to neuromyopathy of the orbicularis oculi muscle was reported in an anorexic patient with vitamin C deficiency [201] and ocular surface symptoms secondary to lagophthalmos have been reported [202]. Although vitamin A deficiency may have implications for ocular surface signs of chronic anorexia nervosa, superficial punctate keratopathy, reduced tear production, and conjunctival squamous metaplasia may occur in the absence of vitamin A deficiency [203]. Further studies are required to determine the role of societal factors in eating disorders and their ocular surface consequences.

3.1.3. Obesity and metabolic syndrome Obesity is a multifactorial disease with complex genetic and environmental risk factors [204]. Alongside high blood pressure, hyperglycemia, and hyperlipidemia, obesity is a risk factor for metabolic syndrome (a cluster of conditions which together increase the risk of heart disease, stroke and type 2 diabetes). The global prevalence of obesity and metabolic syndrome has increased significantly over the past few decades due to imbalanced nutrition, socioeconomic conditions and sedentary lifestyles [204–206]. Obesity has been associated with lower tear break-up time and greater meibomian gland dysfunction and ocular surface disease index scores, relative to a non-obese control group [207]. A study in Chinese adults revealed significant associations between moderate-to-severe meibomian gland dysfunction and being overweight or obese [208]. In a paediatric population, body mass index was associated with meibomian gland tortuosity and reduced lipid layer thickness [209]. Obese participants were more likely to develop dry eye disease compared with those with low body mass index (<23 kg/m²) [210]. This relationship was reversed in the Lifelines study, which found a strong association between both high (measured) body mass index and (measured) hypertension and less dry eye disease, when controlling for other variables [15]. This would suggest there is not a simple relationship between metabolic syndrome, its risk factors, conditions reflective of systemic inflammation and meibomian gland dysfunction or/and dry eye disease, in different population groups [211–213].



3.1.4. Fasting Daytime fasting, either as a ritual practised for religious reasons or as a diet regimen (also known as intermittent fasting), may have impacts on tear production and ocular surface health. After 12 h of fasting, there is a temporary increase in basal tear secretion followed by a decrease [214]. Also, significant changes in the pattern of tear proteins and activity of tear enzymes were observed during fasting in Ramadan (the holy month for Muslims) compared with the previous month [215]. Moreover, religious fasting was associated with significantly increased tear osmolarity, ocular surface disease index score [216] and inflammatory markers [217] and decreased unanesthetized Schirmer value [216] and tear break-up time [217]. There is no report on the ocular surface effects of non-religious intermittent fasting (which is less strict than religious fasting), though potential impacts have been proposed [218]. Since intermittent fasting as a diet regimen is gaining popularity [219], further studies to explore its impact on ocular surface health are recommended.

3.2. Smoking

Nicotine is a drug that can act as both a depressant and a stimulant. It is a naturally occurring alkaloid which is present in cigarettes and tobacco [220].

Smoking is a known cause of tear film alterations [221, 222] but the relationship between smoking and ocular surface diseases is less clear (also see TFOS Lifestyle Report [6]). Cigarette smoke can increase tear interleukin-6, decrease goblet cell density, decrease the secretion of tear MUC5AC [223] and can irritate the ocular surface, resulting in symptoms [224]. Unanesthetized Schirmer score is reduced in smokers compared to non-smokers (13.3 ± 11.5 mm vs 19.0 ± 11.7 mm) [223]. The decrease in goblet cell density in smokers is associated with lissamine green staining of the ocular surface [223].

Population-based studies have not confirmed an elevated risk for dry eye disease with smoking, however.

One study established smoking as a risk factor for dry eye disease [149]

but this has not been confirmed in a systematic review of smoking and eye diseases [225], and the largest population-based Lifelines study has shown a reduced risk of dry eye disease in current smokers, but a higher risk in previous smokers, a result confirmed in a UK-based population study reported in the same paper [15]. The rate of smoking has increased in certain population groups, including women and adolescents [226, 227]. Smoking is often associated with other demographic and societal factors, including family history and social factors [228], unemployment [229], low-income [230], and immigration [231]. There is a positive relationship between smoking and depression, anxiety, and psychological distress, although the evidence does not support a causal role for smoking in developing mental illnesses [232, 233]. Independent relationships between smoking and ocular surface diseases may therefore be confounded by other societal factors.

The use of e-cigarettes and vaping may be considered an emerging societal factor, and this may expand the demographic exposed to nicotine. Smoking nicotine-containing e-cigarettes significantly reduces tear film stability and increases ocular surface staining [234], adversely impacts the tear lipid layer [221], causes changes in conjunctival impression cytology [235], reduces corneal and conjunctival sensitivity [236], increases ocular irritation and decreases anesthetized Schirmer scores [237], alters tear ferning grade [238], increases tear osmolarity [239], increases eyelid margin abnormalities and decreases meibum quality [240]. E-cigarettes may be equally as harmful to the ocular surface as traditional tobacco or cigarettes, although this has not been confirmed in population-based studies. Vaping decreases non-invasive tear break-up time, fluorescein tear break-up time, and tear meniscus height compared to non-vaping controls, with the effect on these ocular surface parameters being worse with higher vaping voltage [241]. However, this study also reported significantly higher Schirmer scores in vapers compared to non-vapers [241], conceivably due to increased tear production from vaping smoke, although this was unproven.

3.3. Exercise Exercise is an effective treatment for chronic systemic diseases including cardiovascular disease [242], where it can reduce systolic blood pressure, fasting glucose, fasting insulin and improve vascular and cognitive function [242, 243]. In diabetic mice, eight weeks of aerobic exercise increased tear secretion and reduced oxidative stress markers in tears [244].

A large population-based study in Japan showed that a lack of physical exercise and sedentary behaviour were strongly linked with increased susceptibility to dry eye [245]. This association was also found in a large population-based study in the Netherlands, but was not present after further correction for 48 comorbidities including conditions that are consequently associated with decreased exercise, such as connective tissue disease and depression, indicating the importance of correction for associated comorbidities in these analyses [15]. In Japanese children, screen time and decreased physical activity was associated with obesity, dry eye and reduced academic performance [246]. In a small study in humans, 30 min of aerobic exercise improved Schirmer score, invasive and non-invasive tear break-up time and reduced levels of inflammation and stress markers in the tear film [247]. Ten weeks of aerobic exercise performed three times per week in 11 participants with dry eye disease improved dry eye symptoms as measured with the DEQ-5 [248]. It is conceivable that parasympathetic innervation to the lacrimal gland, specifically to the acinar blood vessels, is stimulated with exercise, which may increase the secretion of

electrolytes and water ^[249]. There are limited published studies in both dry eye disease and normal participants for a conclusive statement to be made, however.

3.4. Alcohol/caffeine/recreational drug use/abuse

3.4.1. Alcohol (see TFOS lifestyle challenges ^[6] and nutrition ^[3] reports) Orally administered ethanol can be detected in tears, leading to decreased tear break-up time and unanesthetized Schirmer scores ^[250], and increased corneal staining and tear osmolarity compared to controls ^[251]. In a meta-analysis of 10 studies, alcohol consumption was a significant risk factor in dry eye disease, irrespective of age and sex ^[252]. A large population-based study reported alcohol consumption increased the risk of symptomatic dry eye disease in females (odds ratio [OR] 1.095, 95%CI 1.045–1.148) after correction for confounding variables such as demographic and systemic disease factors; but this finding was not significant in males in whom alcohol consumption was found to be protective against symptomatic dry eye disease ^[253]. The oral consumption of alcohol may also induce an upregulation of proinflammatory cytokines in the cornea ^[251].

Chronic consumption of alcohol has been linked to vitamin A deficiency via the induction of ethanol-inducible cytochrome P-450 in the liver ^[254], leading to morphological changes on the ocular surface in the form of conjunctival and corneal keratinization, goblet cell loss ^[255], punctate keratitis, necrosis and corneal ulceration ^[256].

Some large epidemiological studies have reported no impact of alcohol consumption on dry eye disease ^[224,257,258]. Alcohol consumption, however, was noted to be protective for dry eye disease in an older Australian population ^[259].

3.4.2. Caffeine (see TFOS lifestyle challenges report ^[6]) Caffeine is a central nervous stimulant belonging to the methylxanthine family. It is one of the most consumed psychoactive substances and is known to have mild diuretic effect ^[260]. Due to this diuretic effect, caffeine, when consumed in large quantities, has been thought to exacerbate dry eye disease, however, there is little evidence to support this. In a large population survey study of 19,599 participants, the frequency of coffee consumption, based on the number of cups of coffee consumed per day showed no relationship with the risk of dry eye disease ^[261]. In a population-based study in the Netherlands, including 85,302 participants, caffeine intake was calculated by assessing dietary intake of coffee, tea, cola, and energy drinks ^[262]. Caffeine intake was associated with a slightly protective effect on dry eye, after correction for age and sex only. This association disappeared however after additional correction for over 50 possible confounding factors including smoking, alcohol intake and numerous comorbidities ^[262]. Similar findings have been observed using diagnostic criteria other than the Women's Health Study questionnaire for dry eye disease ^[259,263]. There is some evidence for a protective effect of caffeine in dry eye disease from the Beaver Dam Eye study cohort, where participants who did not consume coffee had significantly higher prevalence of dry eye disease compared with those who did (16.6% vs 13.0%) ^[224]. Confounding factors may have influenced this result, however.

The effect of caffeine on tear secretion was studied in a randomised controlled trial of 41 healthy young adults, with a mean age of 23 ± 2.1 years ^[264]. Consumption of caffeine (5 mg/kg of body weight dissolved in 200 mL of water) resulted in increased Schirmer scores (without

anesthetic) assessed at 45 min and 90 min post-consumption ^[264]. Caffeine intake between 5 and 7 mg/kg of body weight increased tear meniscus height in a randomized controlled trial of 78 healthy participants ^[265]. The underlying mechanism is unclear, but polymorphisms in cytochrome P450 1A2 and the adenosine A2a receptor gene may be implicated ^[265]. The effect of caffeine on other ocular surface disease parameters such as tear break-up time, tear osmolarity and ocular surface staining has not been explored in well-controlled studies.

Green tea contains xanthines (such as caffeine), amino acids (such as theanine, glutamic acid, tryptophan, lysine, aspartic acid, glycine, serine, tyrosine, valine, leucine, threonine, and arginine); catechins; polyphenols (such as flavanols, flavandiol, and flavonoids) and trace elements ^[266,267]. Green tea is mostly consumed for its benefits in cardiovascular disease, anti-stress, anti-inflammatory and antioxidative properties, as well as neuroprotective and cholesterol-reducing properties ^[266].

The effect of a single dose of green tea on tear production and quality was assessed in a case control study using the phenol red thread test and tear ferning test ^[268]. Tear film ferning is a measure of tear film quality and the tear fern pattern formed following the drying of tears collected on a glass slide under normal room temperature conditions is assessed qualitatively ^[269]. Normal tears produce a dense fern pattern while in patients with dry eye disease, the pattern is either absent or fragmented ^[270]. There was a reduction in median phenol red thread test length, with 80% of participants showing a reduction in length, and an increase in tear ferning fragmentation 1 h after consumption (2.0 g in 150 mL) ^[267]. The authors hypothesized that the serum lipid oxidative properties of polyphenols observed in a rat model, may be similarly exhibited in human tear film lipids and impact tear film quality. A further hypothesis is that a low concentration of caffeine, between 2 and 4%, may also contribute to the findings ^[267]. In contrast, a comparative study which evaluated the effect of topically-instilled green tea extract compared with artificial tears, reported an improvement in dry eye symptoms (ocular surface disease index), tear break-up time and meibum quality ^[271].

The available evidence would suggest that caffeine seems to offer a benefit to the ocular surface by decreasing dry eye symptoms, increasing tear secretion and tear film stability but the effect of green tea on the ocular surface is equivocal.

3.4.3. Recreational drugs Recreational drug use refers to the unsupervised use of illegal or legal drugs for leisure or pleasure, including analgesics, depressants, hallucinogens and stimulants. Analgesic drugs in this context include narcotics such as heroin, codeine, fentanyl, tramadol and morphine. Depressant drugs inhibit the central nervous system and may lead to drowsiness, coma, sleep, anesthesia, and death, including alcohol, nicotine, barbiturates, and tranquilizers. Hallucinogens induce psychological effects such as distortions from reality, illusions and hallucinations, including marijuana, psilocybin, lysergic acid diethylamide, phencyclidine, peyote and ketamine. Stimulants increase the activity of the central nervous system and bodily activity in general, including cocaine, methamphetamine, and 3,4 methylenedioxymethamphetamine.

The prescribing of opiate analgesics for ophthalmic indications has increased, particularly in people with African heritage, individuals with higher income, and a lower level of education ^[272]. Despite the increasing use

of these drugs in ophthalmology in both post-operative cases and in the treatment of neuropathic pain [273,274] and evidence of persistent opioid use after ocular surgery [275], the effect of opiate analgesics on the ocular surface has not been widely studied (See TFOS Elective Medicines Subcommittee Report [144]). Opioid receptors are present on the human cornea and topically applied opioids may stimulate these receptors to decrease ocular pain [276].

Morphine is used in pain management [277] and is one of the most commonly abused medications [278]. Users of morphine are more likely to be male, experiencing homelessness and unemployment [278]. Topically-applied morphine sulphate in post-surgical abrasions reduced pain and corneal sensation without retarding corneal wound healing [277]. Tramadol, another opiate analgesic, is an analogue of codeine that has been used to manage post-surgical eye pain [279]. There are no randomised controlled trials of its effects on the ocular surface in humans, but corneal sensitivity is reduced within 1–25 min of topical application [280] and temporary blepharospasm has been induced in animal models [281].

While corneal wound healing appears to be unaffected by the topical use of opioids, corneal anaesthesia may alter tear secretion and corneal epithelial physiology [282,283]. Importantly, the corneal analgesic effect is effective only in the presence of inflammation [277].

In animal studies, there was no impact of tear production measured with the Schirmer test following intramuscular tramadol in dogs [284, 285] or with morphine [286] or fentanyl [287]. Heroin use may lead to conjunctival injection [288] and a case of atypical kerato-conjunctival lesions due to transconjunctival heroin abuse has been reported [289].

Barbiturates are sedative and hypnotic agents used in the management of seizures, pre-operative anxiety, insomnia, and the induction of coma. There are limited human studies that directly explore the impact of barbiturates on ocular surface diseases, but one study did find that phenobarbital leads to a transient sicca effect in a patient being managed for seizures [290]. In animal studies, thiopental decreased tear production assessed by unanesthetized Schirmer scores in dogs when used in the induction of anesthesia [291]. The use of anxiolytic medications in patients with depressive or anxiety disorders has been linked to a higher odds ratio of dry eye disease [292,293]. Ketamine, a sedative medication used during surgery reduces tear production in both cats [294] and dogs [295]. Although there are few direct studies, the indirect evidence would suggest that these sedative medications may worsen dry eye disease by decreasing tear production.

Marijuana has psychoactive properties and has been used in medicine for increasing appetite, treating eating disorders and nausea, in the management of pain and chronic inflammation, multiple sclerosis and epilepsy [296]. In humans, marijuana use has been associated with reduced tear secretion [297] and decreased corneal endothelial cell density [298]. In mouse studies, the ocular effect of marijuana via its derivative, tetrahydrocannabinol, through acting on the ocular surface cannabinoid CB1 receptors, appears to be sex dependent as it leads to decreased tear production in males but increased tear production in female mice [299]. While marijuana use may lead to dry eye symptoms [300,301] and a decrease in tear production [297], it may however be useful in the management of corneal neuropathic pain [302]. Topical administration of 1% delta 9-tetrahydrocannabinol results in increased ocular irritation [303].

There is limited evidence of the benefits of cannabis on ocular surface disease and based on available data, marijuana use, especially when smoked, may worsen dry eye disease.

The data regarding the impact of hallucinogens such as psilocybin, and lysergic acid diethylamide are limited, however, conjunctival and corneal erosions have been reported in a case of trans-conjunctival lysergic acid diethylamide application to the inferior conjunctival fornix [304].

Other stimulant drugs such as snorted cocaine have been linked to decreased tear production assessed by unanesthetized Schirmer wetting scores (16.5 ± 10.1 mm in eyes following cocaine use vs 22.5 ± 12.9 mm in control eyes) [305]. Similarly, in individuals who snorted cocaine, there was a significant decrease in tear production, decreased corneal sensitivity, neurotrophic keratitis, and decreased blink rate [306]. Other conditions associated with the use of cocaine include anterior staphyloma [307], corneal ulceration [308,309], epithelial defects and corneal infiltration [310], and infectious keratitis [311]. Similarly, methamphetamine use has been reported to lead to conjunctivitis and corneal melting [312], and keratitis [313]. The mechanism of damage of cocaine and methamphetamine to the ocular surface has not been well studied, but it may well be related to the excessive release of dopamine, which leads to sensory nerve damage [314]. This may lead to a decreased blink rate, worsening exposure keratopathy, neurotrophic keratitis, corneal ulceration and ultimately corneal blindness.

3.5. Cultural and religious beliefs, including traditional medicines

Traditional medicines describe health practices based on animal or plant sources, spiritual or mineral therapies used in the diagnosis, prevention or management of illness or maintenance of general well-being [315]. There is widespread use of traditional medications and practices in developing countries, especially in Africa, India, and South America. Traditional medications may be in the form of vegetative matter, breast milk, plant extracts or animal waste products.

Breast milk has been traditionally used by mothers for the management of conjunctivitis in rural areas in developing countries [316]. The protective mechanism is believed to be due to immunoglobulin A, lysozyme, lymphocytes, macrophages and protease inhibitors present in the colostrum, which confer antibacterial properties [317]. However, complications, including corneal infection and endophthalmitis, have been reported in a prospective study in a tertiary health setting [317]. Another prospective study also reported breast milk to be the most commonly applied traditional eye medicine in patients with corneal ulcers (45.2%) [318]. Other traditional eye medicines include vegetative matter (29.6%), castor oil (11.9%), and hen's blood (5.9%) [318]. The use of traditional eye medications has been associated with hypopyon at presentation, with a risk of central dense corneal scarring [319] and infectious keratitis as well as peripheral corneal ulcers [320]. Patients using traditional eye medicines tend to have a delayed presentation to seek medical attention compared to those using Western medicine [321].

While the harmful effects of breast milk on the ocular surface are well documented, there is also some evidence of benefit. In mouse models, human breast milk improves corneal epithelial damage comparably to cyclosporine [316].





In a prospective animal study comparing the use of breast milk, autologous serum and artificial tears in mice with corneal abrasions, the group receiving topical breast milk drops experienced faster corneal re-epithelization compared to other groups ^[322]. In a study of breast-fed infants ≤ 180 days, breast milk was equally effective in treating eye discharge when compared to sodium azulene sulphonate hydrate 0.02% ophthalmic solution ^[323]. In patients with neurotrophic corneal opacity, especially post-viral infections, breast milk appeared to be effective in improving corneal sensitivity and visual acuity ^[324]. However, some patients developed bacterial conjunctivitis during treatment and the efficacy was poor in diabetics ^[324]. Topical bovine colostrum improves corneal re-epithelization following alkali burns in mice ^[325].

Castor oil is derived from the *Ricinus communis* plant and is used in cosmetics as an emollient (See TFOS Cosmetics Subcommittee Report ^[4]). It has been used as a wound dressing and a drug delivery system ^[326]. It has antibacterial, anti-cancer ^[327], anti-inflammatory, anti-oxidant and wound healing properties, making its use on the ocular surface logical ^[326]. In vivo, ricinoleic acid contained in castor oil is able to produce esters, amides and polymers which cover the ocular surface, decreasing the evaporation of aqueous tears and thus improving tear stability and decreasing ocular surface staining and dry eye symptoms ^[326]. In a randomized controlled trial, topical periocular castor oil significantly decreased ocular surface disease index scores, lid margin thickening, telangiectatic vessels, lash matting, madarosis, cylindrical dandruff and lid wiper epitheliopathy in patients with blepharitis after 4 weeks of use compared to untreated eyes ^[326]. Castor oil, applied topically, appeared safe and effective in decreasing tear film instability, symptoms, and ocular surface staining in strengths of 2% and 5% compared to placebo in a randomised controlled study ^[326]. Though widely believed to be of benefit in eye lash growth, the evidence suggesting the use of castor oil for eye lash elongation is lacking and the evidence for its use in hair growth is weak ^[329].

Poor access to health care facilities, distance from hospitals and illiteracy are some of the reasons for the use of practices that may lead to severe ocular surface diseases due to traditional medicines. Education of, and collaboration with, traditional healers led to a decrease in corneal blindness and changes in the pattern of corneal disease in rural areas in Africa ^[330]. In this study, traditional healers were discouraged from using traditional medicines applied directly to the eyes and they were advised to refer patients if there was no resolution of the ocular disease in three days. After one day of training the healers, a change in the pattern of corneal disease was observed, with bilateral corneal disease decreasing from 31% to 10% ^[330].

Due to religious beliefs, certain traditional practices have become popular in rural areas. Ayurvedic medicine is a form of traditional Indian medicine derived from natural substances such as roots, and herbs for the treatment of the mind and soul. Cow urine is notably used in the preparation of some of the formulations of this type of medicine and this has been used for treating a range of diseases, including coronary artery disease, hypertension, asthma ^[331] and cancer ^[332]. The cow urine is either boiled, or the distillate used ^[331]. Cow urine applied to the eye leads to corneal epithelial defects, corneal edema and decreased vision ^[331].

The type of traditional medicine use varies with cultural practices and geographic diversity. A systematic review reported the widespread use of Kermes, a red dye obtained from an insect *Kermes ilicis* in Saudi Arabia ^[315]. Kermes leads to severe ocular surface toxicity and cicatricial conjunctivitis ^[333]. Alum, a hydrated salt comprised of potassium aluminium sulphate used in making foods, as an astringent agent, and also as a flocculating agent ^[315], causes severe keratitis, corneal thinning, scarring and decreased vision ^[334]. In animal models, garlic extract has exhibited antibiotic properties similar to gentamycin and has been used traditionally in parts of Nigeria, Western Africa ^[335], however, such vegetative extracts may also act as sources of ocular infections. Similarly, honey, used for its anti-inflammatory, anti-bacterial and anti-oxidant properties, has been used in the management of ocular surface diseases such as blepharitis ^[336], conjunctivitis ^[337], dry eye disease and tear film stability in meibomian gland dysfunction ^[338, 339], and even vernal keratoconjunctivitis ^[340]. Despite these numerous benefits, honey can become contaminated and has been implicated in *Acanthamoeba* keratitis ^[341]. Aloe vera is another naturally occurring plant with sap that has many benefits ^[342]. However, it has also been associated with ocular infections ^[343], and these plants (or their sap), when not properly stored, may become contaminated and become potential sources of infection ^[315]. Ushaar (*Calotropis procera*) is a xerophytic shrub found in Asia, Africa and some parts of South America, which can induce corneal toxicity ^[344]. The traditional Chinese medicine, Qiming may hold promise in improving tear film stability and secretion, as well as corneal wound healing properties ^[345]. Further studies are needed to thoroughly determine its therapeutic value.

Homeopathic medicines have been used to reduce ocular symptoms associated with allergic rhinitis, and a systematic review determined a small positive effect of *Galphimia glauca*

or a homeopathic nasal spray on ocular and nasal symptoms^[346]. However, risk of bias and lack of appropriate masking in these studies warrants further randomised control trials to determine their true efficacy.

While some traditional medicines clearly have benefits to the ocular surface, they may act as a source of microorganisms, induce toxic keratopathy and pose a threat to vision. Where medications are not manufactured with strict hygiene protocols and tested for efficacy and safety, they should be used with caution. Their use should be restricted to those with no or limited history of ocular toxicity and by trained skilled practitioners with a low threshold for early referral, if conditions do not resolve quickly. In the absence of obvious improvement, or with worsening of the condition, the use of these agents should be discontinued, and appropriate management instituted.

3.6. Hobbies, recreational and sport-related factors

3.6.1. Recreational and sport-related factors Although sports and recreation have numerous physical and mental benefits, traumatic injuries to the ocular surface may occur. In a retrospective study in the USA, the most common sports and recreation activities associated with eye injury in children younger than 17 years of age, were basketball (15.9%), baseball and softball (15.2%), and nonpowder guns (10.6%)^[347]. In Australia, cycling, football, tennis, trampolining, fishing and swimming were the sports responsible for the greatest number of eye injuries^[348].

Sports such as soccer and hockey increase the risk of sight threatening eye injuries. A study analyzed the trends of soccer-related ocular injuries in the USA from 2010 to 2019, and found that serious visual consequences were associated with soccer-related ocular injury^[349]. Field hockey is a popular high school sport among girls in the USA. Although not common, serious eye injuries and vision damages can happen when players are struck by the stick or ball during the game^[350]. The National Federation of State High School Associations in the USA issued a protective eyewear mandate in sanctioned competitions in 2011. A prospective cohort study evaluated the incidence of eye/orbital injuries during two seasons of play before and after the national protective eyewear mandate and demonstrated that the mandate was associated with a decreased incidence and severity of eye/orbital injuries^[351].

Toy guns, usually a miniature non-functioning replica of a gun, but those which may fire caps or pellets, can also cause a range of traumatic injuries. A study from Finland found that toy guns can cause serious eye trauma, including blunt ocular trauma and corneal abrasions^[352]. Both players and bystanders are recommended to use protective eyewear during the entire game^[352]. Similar results were reported from a study on children in Canada^[353]. A retrospective study reviewed the characteristics and outcomes of patients treated for ball bearing and pellet gun-related open globe injuries from January 2002 to November 2017^[354]. The result indicated that ball bearing or pellet guns could cause devastating visual damage, associated with multiple complications and the need for further surgery beyond the initial repair^[354]. These results emphasize the importance of eye protection during the use of toy guns.

Based on a review of publications from 1980 to 2014 describing eye trauma and recreational fishing, sharp hooks and heavy sinker weights projected at high speed, can cause severe eye injuries and significant vision loss^[355]. Open and

closed globe injuries occurred 9x more commonly in males and were most likely to occur via a hook^[355]. A retrospective observational analysis of the data from The United States Eye Injury Registry found that fishing-related eye injuries accounted for 19.5% of all sports related eye injuries and 28.2% of the open-globe injuries reported to the registry from 1998 to 2004^[356].

3.6.1.1. Firework injuries. Fireworks are popular but can lead to severe eye injuries. Firework-related eye injuries and associated consequences were reviewed by the International Globe and Adnexal Trauma Epidemiology Study: Fireworks Study Group^[357]. Cross-sectional or retrospective studies have been carried out in various countries, including the USA^[358], China^[359], India^[360], Germany^[361,362], Nepal^[363] and the Netherlands and Finland^[364], to quantify the national prevalence of firework-related ocular injuries. Firework-related ocular injuries mostly occur in young males and the severity of the injuries ranged from mild irritation to ruptured globes. More severe injuries have major impacts on ocular morbidity and visual acuity. To significantly reduce firework-inflicted trauma, a ban of private fireworks in densely populated areas and in the vicinity of children should be considered. Greater education about, and prophylaxis for, firework-related eye injuries would help to reduce the risk of severe consequences.

3.6.2. Ultraviolet light exposure Outdoor or indoor exposure to ultraviolet light is common due to sporting or vocational exposures, or due to societal expectations of having a tanned appearance (See also Section 4.2 and TFOS Environmental Subcommittee Report^[7]). Persistent exposure can occur in outdoor and winter sports, including water sports, skiing, snowboarding and distance running, and persistent exposure is related to ocular surface diseases including pterygium, droplet keratopathy and snow blindness^[365]. The level of protection for athletes and workers is dependent on the jurisdiction and level of regulation. Ultraviolet light eye protection in athletics is frequently mandated through uniform and eye protection policies at club and competition level^[366].

Indoor suntanning is a popular way of enhancing skin tones for people with light skin color (See TFOS Cosmetics Subcommittee Report^[4]). Because of a lack of universally adopted laws or guidelines, eye protection during indoor suntanning is not obligatory. A prospective study found ultraviolet light exposure during indoor suntanning could cause significant microstructural changes to the cornea and the bulbar conjunctiva^[367]. Identifying sports and recreation-associated risk factors will help in the development of injury prevention strategies to protect eye health.

3.7. Societal supports or societal pressures (see TFOS Elective Medications subcommittee report^[144])

Disfiguring eye conditions have major impacts on psychosocial functioning. In a multicenter study, 10–49% of the patients with disfiguring eye conditions had high levels of psychosocial distress, evidenced by lower scores in standardized measures of anxiety, depression, appearance-related distress, and quality of life^[368]. Similarly, almost 40% of ophthalmic clinic patients reported high levels of distress and dysfunction in relation to their appearance^[369]. A prospective observational study in adolescents with manifest exotropia showed these individuals to experience abnormal scores on psychological distress evaluation scales and surgical correction significantly improved the outcomes of all these scales^[370]. Patients wearing eye prosthetics tend to have a higher risk of

depression, anxiety and stress, especially in employment, leisure and social functioning issues ^[371].

While appearance-changing diseases significantly impact mental health, cosmetic surgeries can improve personal wellbeing, self-esteem, and different aspects of daily life. A retrospective study found that blepharoplasty operations significantly improved quality of life for patients ^[372]. Cosmetic surgeries can impact ocular surface health (See TFOS Cosmetics Subcommittee Report). To create the appearance of a double eyelid, cosmetic blepharoplasty and double eyelid tapes have become popular in East Asian countries (TFOS Cosmetics Subcommittee Report ^[4]). Upper eyelid surgery results in a temporary decrease in ocular surface sensation that returns to baseline after one month ^[373]. Cosmetic double-eyelid blepharoplasty may temporarily affect tear film dynamics and aggravate dry eye symptoms in young female patients, which generally recover within 3 months ^[374]. Similar results were observed in patients undergoing cosmetic transcutaneous lower blepharoplasty, which affects the ocular surface and tear stability for three months ^[375]. Double eyelid tapes worn for two weeks can increase conjunctival staining, corneal staining, signs of meibomian gland dysfunction and incomplete blinking, and significantly decrease tear break-up time and intraocular pressure ^[376]. The association between cosmetic blepharoplasty and dry eye disease has been previously reviewed ^[374].

Botulinum toxin type A is an injectable neurotoxin that is widely used to treat eye diseases including strabismus, blepharospasm and facial wrinkles around the eyes (see TFOS Elective Medications ^[144] and TFOS Cosmetics Subcommittee ^[4] Reports). The impact of Botulinum toxin injection on the ocular surface is controversial, as periocular Botulinum toxin may cause dry eye disease through reduced lacrimal gland secretion and increased tear evaporation due to adverse events, such as eyelid malposition and abnormal blinking ^[345]. Conversely, injection in the medial eyelids can improve dry eye disease by decreasing tear drainage from the nasolacrimal duct ^[345].

3.8. Other determinants or choices

Cosmetic, sporting, occupational or other lifestyle preferences may influence an individual's choice to wear contact lenses (see TFOS Contact Lenses Subcommittee Report ^[377]) or undertake corneal refractive surgery (see TFOS Elective Medications Subcommittee Report ^[144]). Appearance concerns are more frequently reported by women than men and there is greater uptake of contact lens wear ^[378] with attendant ocular surface sequelae, and particularly complications associated with dry eye symptoms are more prevalent in females than males ^[378]. Women are also more frequent candidates for corneal refractive surgery than men ^[379] and more prone to iatrogenic dry eye disease following refractive or cataract surgery ^[380]. While such refractive choices may be associated with the development of ocular surface diseases, including dry eye disease ^[381], they may also exacerbate existing ocular surface diseases.

Eyelid tattooing is a popular cosmetic procedure for women in certain countries, although there are adverse effects on the ocular surface (See TFOS Elective Medications ^[144] and TFOS Cosmetic Subcommittee ^[4] Reports). These include a risk of direct mechanical trauma from the needle, which may conceivably cause damage to the meibomian glands. Meibomian gland loss, evidenced by a lower meiboscore, has been reported in those with eyelid tattoos ^[382].

Tattoo ink pigments persist as pigment granules in the epidermis and dermis ^[383]. Most of the residual pigment is located within the macrophages in the dermis and, focally, in the endomysial connective tissue of the superficial orbicularis oculi muscle ^[383]. Tattoo ink, particularly those containing para-phenylenediamine ^[384] or black henna ^[385] may induce contact dermatitis.

4. Living and working conditions

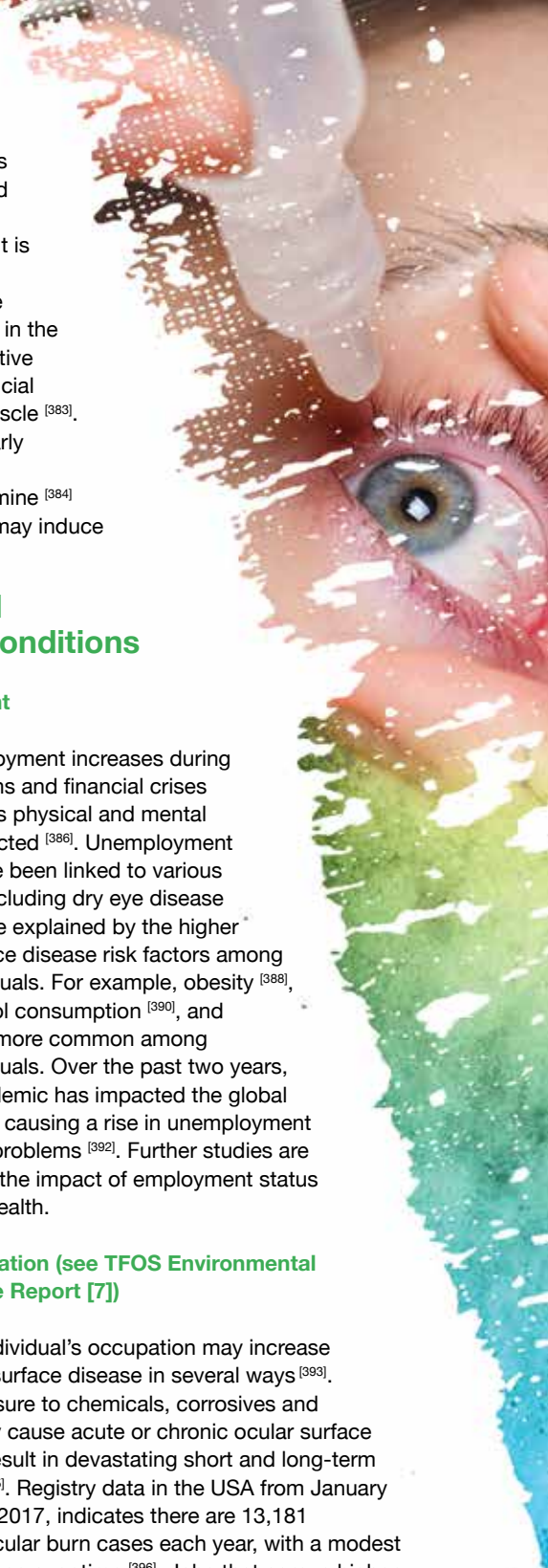
4.1. Unemployment

The rate of unemployment increases during economic downturns and financial crises and directly impacts physical and mental health of those affected ^[386]. Unemployment and retirement have been linked to various health problems, including dry eye disease ^[210,387]. This might be explained by the higher rate of ocular surface disease risk factors among unemployed individuals. For example, obesity ^[388], smoking ^[389], alcohol consumption ^[390], and depression ^[391] are more common among unemployed individuals. Over the past two years, the COVID-19 pandemic has impacted the global economy, including causing a rise in unemployment and related health problems ^[392]. Further studies are required to explore the impact of employment status on ocular surface health.

4.2. Type of occupation (see TFOS Environmental Subcommittee Report [7])

The nature of an individual's occupation may increase their risk of ocular surface disease in several ways ^[393]. Occupational exposure to chemicals, corrosives and excessive heat may cause acute or chronic ocular surface injury, which may result in devastating short and long-term complications ^[394,395]. Registry data in the USA from January 2013 to December 2017, indicates there are 13,181 newly diagnosed ocular burn cases each year, with a modest increase in prevalence over time ^[396]. Jobs that carry a higher risk of ocular surface burn include cleaners, miners, construction workers, laboratory staff, food service industry workers, agricultural workers, fire workers, and mechanics ^[397]. Factors associated with occupational ocular injury are lack of use of protective eyewear at time of injury, male sex, exposure to biological or chemical hazards and risk-taking behaviour ^[398].

In rural populations, open globe injuries are more commonly seen in association with agricultural occupations ^[399]. While ocular trauma is a well-established predisposing factor for infectious keratitis, particularly in rural and low income regions ^[62], ocular trauma due to agricultural injuries in farmers is associated with a higher risk of infectious keratitis ^[63].



Environmental factors such as sunlight and air pollution increase the risk of ocular surface diseases in outdoor workers compared with indoor workers [393,400,401]. Outdoor workers with prolonged sunlight exposure are at higher risk of developing pterygium and climatic droplet keratopathy [402,403]. One large scale study showed agricultural workers to have a lower risk of dry eye disease [393]. Certain indoor environments, such as those having low humidity and high levels of particulate matter of 2.5 µm or less, have been associated with dry eye symptoms [404]. The prevalence of dry eye disease in office workers with prolonged use of visual display terminals ranged between 9.5% and 87.5% [20,405]. This very wide range in prevalence has been attributed to the use of different diagnostic criteria in studies of dry eye disease [20].

Animal handlers might be at higher risk for developing ocular surface injuries. Keratitis and ophthalmia nodosa have been reported repeatedly following handling of Tarantula spiders, which have become popular pets [406–408]. Ocular surface chemical injuries following exposure to sheep, turkey, and fish bile have been reported in abattoir workers [409–411]. Ocular bee stings may occur as an occupational hazard in beekeepers or farmers and can cause severe corneal or conjunctival inflammation, especially if there is a retained stinger [412–414].

Since the emergence of the COVID-19 pandemic, working and studying from home and prolonged use of face masks have resulted in an increased prevalence of dry eye symptoms (see Section 8). Occupations that require longer screen time [393] and/or continued face mask use (see section 8) or a combination of both might conceivably be at higher risk for developing or worsening of dry eye disease. Working night shifts is another occupational risk factor which is associated with meibomian gland dysfunction, tear film instability and exacerbation of dry eye symptoms [415,416].

4.3. Water and sanitation

Reduced access to clean water and sanitation may increase the risk of ocular surface diseases, particularly in the context of trachoma. A systematic review of 47 studies found that access to sanitation was associated with less trachoma, as measured by the presence of trachomatous inflammation-follicular, trachomatous inflammation-intense or *C. trachomatis* infection [417]. Reduced odds of trachomatous inflammation, of either form, were also found with having a clean face, and at least once daily face washing, soap use and daily bathing practices [417]. Conversely, living within 1 km of a water source was not significantly associated with trachomatous inflammation or *C. trachomatis* infection [417]. In Ethiopia, where 77 million people live in trachoma-endemic areas, a systematic review of 29 studies investigating associations between trachoma and access to water supply, sanitation and face hygiene revealed that households with no toilet facilities, no access to improved water and the lack of daily face washing in children showed increased odds of exhibiting active trachoma [418].

There are many other ocular diseases that can be directly attributable to contamination of water bodies by various chemical and pathogens. These can occur through toxic, allergic, inflammatory or infective mechanisms [419]. Specific water-borne ocular infections include *Acanthamoeba* keratitis, Giardiasis, Toxoplasmosis, Gnathostomiasis, Coenurosis, *Pseudomonas aeruginosa* keratitis, Melioidosis, Leptospirosis, Toxocariasis, and Adenoviral disease [419], although some organisms are recognized to have additional environmental sources.

Climate change will likely result in new hazards and water contaminants that may lead to further or changed ocular diseases [419].

4.4. Education and childhood education

Education and childhood education may impact the risk of ocular surface diseases. There is a well-established link between education and poverty, socioeconomic class and access to health services, which affects both the prevalence and severity of a range of both systemic diseases [420] and ocular diseases [421]. Education is linked to better nutrition and therefore health consequences. Likewise, ocular diseases may conceivably impact societal factors, particularly those diseases which affect the quality of vision and may impact academic performance.

Infectious keratitis is more common in those with a low educational level [63–65]. There is a strong association between a low education level and a higher risk of both poorer visual outcome and infectious corneal blindness [64,65]. Having a higher education diploma was associated with an increased risk of dry eye disease in a large population-based study in the Netherlands, which persisted after correction for age, sex and other possible confounding comorbidities [15]. A possible residual confounding factor in this relationship may be increased screen use with higher education occupations.

Reduced attention and concentration is reported in dry eye disease models [422], conceivably due to reduced blinking and resulting pathways to neural connections and brain stimulation, as well as diminished and variable optical performance in dry eye disease [423]. It could be argued that in the context of the increasing dominance of digital screens, eye strain and dry eye symptoms further increase, leading to a deeper lack of concentration and perpetuating this reduced performance cycle. There is evidence for increasing screen time and more time spent on remote education during the pandemic, with screen time reportedly doubling [424] (See sections 6, 7, 8, and the TFOS Digital Subcommittee Report [8]). Screen time has also been reported to be linked to dry eye symptoms in children [425], especially with the use of screens before bedtime [246] and higher screen times are associated with worse school performance [246]. While the mechanisms underlying these effects are unclear, it does appear that screen use is associated with dry eye disease and reduced academic performance [426]. Evidence for the influence of short-wave blue light on these diseases is limited and there is no evidence of the efficacy of protective devices [427,428].

4.5. Poverty and socioeconomic status

Socioeconomic status is an identifiable and well-reported societal factor contributing to the burden of ocular surface disease. There is a higher prevalence of a range of eye diseases in the homeless [429]. Neglected tropical diseases such as trachoma are highly prevalent in low- and middle-income countries and poorer individuals. The SAFE strategy (Surgery, Antibiotics, Facial Cleanliness and Environmental Improvement), proposed by the World Health Organization, includes many lifestyle modifications in endemic areas to eliminate trachoma. Several studies have demonstrated the efficiency of these strategies, however, the way of implementing them varies from study to study, as well as from region to region [417]. Several countries have developed intensive brigades, as well as prevention and control programs to target this disease. Implementing

effective policies largely relies on targeting core groups and relevant societal factors in the remaining endemic areas, worldwide [430].

In addition to trachoma, fungal keratitis has a strong relationship with gross domestic product per capita of the region. A higher proportion of fungal keratitis compared with all infectious keratitis is strongly associated with low gross domestic product per capita [129]. Similarly, a low socioeconomic status and/or poverty are associated with a higher risk of infectious corneal blindness [64].

Evaluating and improving accessibility to ophthalmic diagnosis and treatment for all strata of society is important in improving treatable and preventable ocular surface diseases. Health economic analyses in ocular surface diseases are scarce, however, the great majority of them demonstrate interventions and treatments to be cost-effective [431]. Conceivably, the surge in uptake of telemedicine could prove to be a cost-minimizing alternative for screening and management of some ocular conditions [432], particularly for patients in remote areas or those lacking access to appropriate care.

4.6. Incarceration

Prison populations experience adverse health outcomes due to lack of access to services, delay in accessing appropriate care, limitations in nutrition and lack of awareness. Health and eye health outcomes may be further compromised due to the overlay of other societal factors, including the overrepresentation of marginalized groups in prisons, low education, and poverty [433] and may be exacerbated in regions with low gross domestic product per capita. There are limited studies of ocular surface disease in prison populations. Ocular surface conditions that are over-represented in prison populations include allergic conjunctivitis, pterygia and xerophthalmia [434]. In a cross-sectional study in a Kenyan prison population, 24% of male prisoners had xerophthalmia [435].

All references available here:



References:

- [1] Whitehead M, Dahlgren G. Policies and strategies to promote social equity in health. Stockholm, Sweden: Institute for Future Studies; 1991.
- [2] Rice L, Sara R. Updating the determinants of health model in the Information Age. *Health Promot Int* 2019;34:1241–9.
- [3] Markoulli M, Arcot J, Ahmad S, Arita R, Benitez-del-Castillo J, Caffery B, et al. TFOS Lifestyle: impact of nutrition on the ocular surface. *Ocul Surf* 2023.
- [4] Sullivan DA, da Costa AX, Del Duca E, Doll T, Grupcheva CN, Lazreg S, et al. TFOS Lifestyle: impact of cosmetics on the ocular surface. *Ocul Surf* 2023.
- [5] Gomes JAP, Azar DT, Baudouin C, Bitton E, Chen W, Hafezi F, et al. TFOS Lifestyle: impact of elective medications and procedures on the ocular surface. *Ocul Surf* 2023.
- [6] Galor A, Britten-Jones AC, Feng Y, Ferrari G, Goldblum D, Gupta PK, et al. TFOS Lifestyle: impact of lifestyle challenges on the ocular surface. *Ocul Surf* 2023.
- [7] Alves M, Asbell P, Dogru M, Giannaccare G, Grau A, Gregory D, et al. TFOS Lifestyle: impact of environmental conditions on the ocular surface. *Ocul Surf* 2023.
- [8] Wolffsohn JS, Lingham G, Downie LE, Huntjens B, Inomata T, Jivraj S, et al. TFOS Lifestyle: impact of the digital environment on the ocular surface. *Ocul Surf* 2023.
- [9] Downie LE, Britten-Jones AC, Hogg RE, Jalbert I, Li T, Lingham G, et al. Advancing the evaluation and synthesis of research evidence for the TFOS lifestyle workshop: report of the evidence quality subcommittee. *Ocul Surf* 2023.
- [10] Stapleton F, Alves M, Bunya VY, Jalbert I, Lekhanont K, Malet F, et al. TFOS DEWS II epidemiology report. *Ocul Surf* 2017;15:334–65.
- [11] Arita R, Mizoguchi T, Kawashima M, Fukuoka S, Koh S, Shirakawa R, et al. Meibomian gland dysfunction and dry eye are similar but different based on a population-based study: the hirado-takushima study in Japan. *Am J Ophthalmol* 2019;207:410–8.
- [12] Castro JS, Selegatto IB, Castro RS, Miranda ECM, de Vasconcelos JPC, de Carvalho KM, et al. Prevalence and Risk Factors of self-reported dry eye in Brazil using a short symptom questionnaire. *Sci Rep* 2018;8:2076.
- [13] Farrand KF, Fridman M, Stillman I, Schaumberg DA. Prevalence of diagnosed dry eye disease in the United States among adults aged 18 Years and older. *Am J Ophthalmol* 2017;182:90–8.
- [14] Mill'an A, Viso E, Gude F, Parafita-Fern'andez A, Mora'na N, Rodríguez-Ares MT. Incidence and risk factors of dry eye in a Spanish adult population: 11-year follow-up from the saln'es eye study. *Cornea* 2018;37:1527–34.
- [15] Vehoř J, Snieder H, Jansonius N, Hammond CJ. Prevalence and risk factors of dry eye in 79,866 participants of the population-based Lifelines cohort study in The Netherlands. *Ocul Surf* 2021;19:83–93.
- [16] Man REK, Veerappan AR, Tan SP, Fenwick EK, Sabanayagam C, Chua J, et al. Incidence and risk factors of symptomatic dry eye disease in Asian Malays from the Singapore Malay Eye Study. *Ocul Surf* 2017;15:742–8.
- [17] Paulsen AJ, Cruickshanks KJ, Fischer ME, Huang GH, Klein BE, Klein R, et al. Dry eye in the Beaver Dam Offspring Study: prevalence, risk factors, and health-related quality of life. *Am J Ophthalmol* 2014;157:799–806.
- [18] Tan LL, Morgan P, Cai ZQ, Straughan RA. Prevalence of and risk factors for symptomatic dry eye disease in Singapore. *Clin Exp Optom* 2015;98:45–53.
- [19] Dana R, Bradley JL, Guerin A, Pivneva I, Stillman I, Evans AM, et al. Estimated prevalence and incidence of dry eye disease based on coding analysis of a large, all-age United States health care system. *Am J Ophthalmol* 2019;202:47–54.
- [20] Courtin R, Pereira B, Naughton G, Chamoux A, Chiambaretta F, Lanhers C, et al. Prevalence of dry eye disease in visual display terminal workers: a systematic review and meta-analysis. *BMJ Open* 2016;6:e009675.
- [21] Liu NN, Liu L, Li J, Sun YZ. Prevalence of and risk factors for dry eye symptom in mainland China: a systematic review and meta-analysis. *J Ophthalmol* 2014;2014:748654.
- [22] Song P, Xia W, Wang M, Chang X, Wang J, Jin S, et al. Variations of dry eye disease prevalence by age, sex and geographic characteristics in China: a systematic review and meta-analysis. *J Glob Health* 2018;8:020503.
- [23] Uchino M. What we know about the epidemiology of dry eye disease in Japan.
- [38] Li Y, Lu J, Zhou Q, Wang C, Zeng Q, Chen T, et al. Analysis of clinical and regional distribution characteristics of obstructive meibomian gland dysfunction in China: a multicenter study. *Curr Eye Res* 2020;45:1373–9.
- [39] Viso E, Rodríguez-Ares MT, Abelenda D, Oub'na B, Gude F. Prevalence of asymptomatic and symptomatic meibomian gland dysfunction in the general population of Spain. *Invest Ophthalmol Vis Sci* 2012;53:2601–6.
- [40] Hassanzadeh S, Varmaghani M, Zarei-Ghanavati S, Heravian Shandiz J, Azimi Khorasani A. Global prevalence of meibomian gland dysfunction: a systematic review and meta-analysis. *Ocul Immunol Inflamm* 2021;29:66–75.
- [41] Zhang AC, Muntz A, Wang MTM, Craig JP, Downie LE. Ocular Demodex: a systematic review of the clinical literature. *Ophthalmic Physiol Opt* 2020;40: 389–432.
- [42] Suzuki T, Kitazawa K, Cho Y, Yoshida M, Okumura T, Sato A, et al. Alteration in meibum lipid composition and subjective symptoms due to aging and meibomian gland dysfunction. *Ocul Surf* 2021.
- [43] Sullivan BD, Evans JE, Dana MR, Sullivan DA. Influence of aging on the polar and neutral lipid profiles in human meibomian gland secretions. *Arch Ophthalmol* 2006; 124:1286–92.
- [44] Obata H. Anatomy and histopathology of human meibomian gland. *Cornea* 2002; 21:S70–4.
- [45] Akowuah PK, Kobia-Acquah E, Donkor R, Arthur C, Senanu EN, Dadzie EE, et al. Prevalence of meibomian gland dysfunction in Africa: a systematic review and meta-analysis of observational studies. *Ophthalmic Epidemiol* 2021;1–10.
- [46] Siak JJ, Tong L, Wong WL, Cajucom-Uy H, Rosman M, Saw SM, et al. Prevalence and risk factors of meibomian gland dysfunction: the Singapore Malay eye study. *Cornea* 2012;31:1223–8.
- [47] Hashemi H, Rastad H, Emamian MH, Fotouhi A. Meibomian gland dysfunction and its determinants in Iranian adults: a population-based study. *Contact Lens Anterior Eye* 2017;40:213–6.
- [48] Gurnus K, Pflugfelder SC. Increasing prevalence and severity of conjunctivochalasis with aging detected by anterior segment optical coherence tomography. *Am J Ophthalmol* 2013;155: 238–42.e2.
- [49] Marmalidou A, Kheirkhah A, Dana R. Conjunctivochalasis: a systematic review. *Surv Ophthalmol* 2018;63:554–64.
- [50] Hashemi H, Rastad H, Emamian MH, Fotouhi A. Conjunctivochalasis and related factors in an adult population of Iran. *Eye Contact Lens* 2018;44(Suppl 1). S206s9.
- [51] Mimura T, Yamagami S, Usui T, Funatsu H, Mimura Y, Noma H, et al. Changes of conjunctivochalasis with age in a hospital-based study. *Am J Ophthalmol* 2009; 147:171–7. e1.
- [52] Poh S, Lee R, Gao J, Tan C, Gupta P, Sabanayagam C, et al. Factors that influence tear meniscus area and conjunctivochalasis: the Singapore Indian eye study. *Ophthalmic Epidemiol* 2018;25:70–8. *Invest Ophthalmol Vis Sci* 2018;59:1–6.

- [24] Akowuah PK, Kobia-Acquah E. Prevalence of dry eye disease in Africa: a systematic review and meta-analysis. *Optom Vis Sci* 2020;97:1089–98.
- [25] Asiedu K, Kyei S, Boampong F, Ocansey S. Symptomatic dry eye and its associated factors: a study of university undergraduate students in Ghana. *Eye Contact Lens* 2017;43:262–6.
- [26] Caffery B, Srinivasan S, Reaume CJ, Fischer A, Cappadocia D, Siffel C, et al. Prevalence of dry eye disease in Ontario, Canada: a population-based survey. *Ocul Surf* 2019;17:526–31.
- [27] García-Ayuso D, Di Pierdomenico J, Moya-Rodríguez E, Vallente-Soriano FJ, Galindo-Romero C, Sobrado-Calvo P. Assessment of dry eye symptoms among university students during the COVID-19 pandemic. *Clin Exp Optom* 2021:1–7.
- [28] Garza-Le' on M, Valencia-Garza M, Martínez-Leal B, Villarreal-Pe'na P, MarcosAbdala HG, Cort'ez-Guajardo AL, et al. Prevalence of ocular surface disease symptoms and risk factors in group of university students in Monterrey, Mexico. *J Ophthalmic Inflamm Infect* 2016;6:44.
- [29] Hung N, Kang EY, Lee TW, Chen TH, Shyu YC, Sun CC. The risks of corneal surface damage in aqueous-deficient dry eye disease: a 17-year population-based study in taiwan. *Am J Ophthalmol* 2021;227:231–9.
- [30] Li S, He J, Chen Q, Zhu J, Zou H, Xu X. Ocular surface health in Shanghai University students: a cross-sectional study. *BMC Ophthalmol* 2018;18:245.
- [31] Supiyaphun C, Jongkhajornpong P, Rattanasiri S, Lekhanont K. Prevalence and risk factors of dry eye disease among University Students in Bangkok, Thailand. *PLoS One* 2021;16:e0258217.
- [32] Uchino M, Dogru M, Uchino Y, Fukagawa K, Shimamura S, Takebayashi T, et al. Japan Ministry of Health study on prevalence of dry eye disease among Japanese high school students. *Am J Ophthalmol* 2008;146:925–9. e2.
- [33] Yang I, Wakamatsu T, Sacho IBI, Fazzi JH, de Aquino AC, Ayub G, et al. Prevalence and associated risk factors for dry eye disease among Brazilian undergraduate students. *PLoS One* 2021;16:e0259399.
- [34] Zhang Y, Chen H, Wu X. Prevalence and risk factors associated with dry eye syndrome among senior high school students in a county of Shandong Province, China. *Ophthalmic Epidemiol* 2012;19:226–30.
- [35] Vehof J, Wang B, Kozareva D, Hysi PG, Snieder H, Hammond CJ. The heritability of dry eye disease in a female twin cohort. *Invest Ophthalmol Vis Sci* 2014;55: 7278–83.
- [36] Chhadva P, Goldhardt R, Galor A. Meibomian gland disease: the role of gland dysfunction in dry eye disease. *Ophthalmology* 2017;124. S20–s6.
- [37] Schaumberg DA, Nichols JJ, Papas EB, Tong H, Uchino M, Nichols KK. The international workshop on meibomian gland dysfunction: report of the subcommittee on the epidemiology of, and associated risk factors for, MGD. *Invest Ophthalmol Vis Sci* 2011;52:1994–2005.
- [38] Zhang X, Li Q, Zou H, Peng J, Shi C, Zhou H, et al. Assessing the severity of conjunctivochalasis in a senile population: a community-based epidemiology study in Shanghai, China. *BMC Publ Health* 2011;11:198.
- [39] Le Q, Xiang J, Cui X, Zhou X, Xu J. Prevalence and associated factors of pinguecula in a rural population in Shanghai, Eastern China. *Ophthalmic Epidemiol* 2015;22:130–8.
- [40] Liu L, Wu J, Geng J, Yuan Z, Huang D. Geographical prevalence and risk factors for pterygium: a systematic review and meta-analysis. *BMJ Open* 2013;3: e003787.
- [41] Rezvan F, Khabazkhoob M, Hooshmand E, Yekta A, Saatchi M, Hashemi H. Prevalence and risk factors of pterygium: a systematic review and meta-analysis. *Surv Ophthalmol* 2018;63:719–35.
- [42] Song P, Chang X, Wang M, An L. Variations of pterygium prevalence by age, gender and geographic characteristics in China: a systematic review and metaanalysis. *PLoS One* 2017;12:e0174587.
- [43] Modenese A, Gobba F. Occupational exposure to solar radiation at different latitudes and pterygium: a systematic review of the last 10 Years of scientific literature. *Int J Environ Res Publ Health* 2017;15.
- [44] Bikbov MM, Zainullin RM, Kazakbaeva GM, Gilmanshin TR, Salavatova VF, Arslangareeva II, et al. Pterygium prevalence and its associations in a Russian population: the ural eye and medical study. *Am J Ophthalmol* 2019;205:27–34.
- [45] Wang Y, Shan G, Gan L, Qian Y, Chen T, Wang H, et al. Prevalence and associated factors for pterygium in Han and Mongolian adults: a cross-sectional study in inner Mongolian, China. *BMC Ophthalmol* 2020;20:45.
- [46] Rim TH, Kang MJ, Choi M, Seo KY, Kim SS. The incidence and prevalence of pterygium in South Korea: a 10-year population-based Korean cohort study. *PLoS One* 2017;12:e0171954.
- [47] Stapleton F. The epidemiology of infectious keratitis. *Ocul Surf* 2021. <https://doi.org/10.1016/j.jtos.2021.08.007>.
- [48] Arunga S, Kintoki GM, Gichuhi S, Onyango J, Ayebazibwe B, Newton R, et al. Risk factors of microbial keratitis in Uganda: a case control study. *Ophthalmic Epidemiol* 2020;27:98–104.
- [49] Song X, Xie L, Tan X, Wang Z, Yang Y, Yuan Y, et al. A multi-center, cross-sectional study on the burden of infectious keratitis in China. *PLoS One* 2014;9: e113843.
- [50] Chidambaram JD, Venkatesh Prajna N, Srikanthi P, Lanjewar S, Shah M, Elakkiya S, et al. Epidemiology, risk factors, and clinical outcomes in severe microbial keratitis in South India. *Ophthalmic Epidemiol* 2018;25:297–305.
- [51] Koh YY, Sun CC, Hsiao CH. Epidemiology and the estimated burden of microbial keratitis on the health care system in taiwan: a 14-year population-based study. *Am J Ophthalmol* 2020;220:152–9.
- [52] 190 F. Stapleton et al. *The Ocular Surface* 28 (2023) 165–199
- [53] Bardach AE, Palermo C, Alconada T, Sandoval M, Balan DJ, Nieto Guevara J, et al. Herpes zoster epidemiology in Latin America: a systematic review and metaanalysis. *PLoS One* 2021;16:e0255877.
- [54] Kawai K, Gebremeskel BG, Acosta CJ. Systematic review of incidence and complications of herpes zoster: towards a global perspective. *BMJ Open* 2014;4: e004833.
- [55] Patki A, Vora A, Parikh R, Kolhapure S, Agrawal A, Dash R. Herpes zoster in outpatient departments of healthcare centers in India: a review of literature. *Hum Vaccines Immunother* 2021;17:4155–62.
- [56] Pinchinat S, Cebri'an-Cuenca AM, Bricout H, Johnson RW. Similar herpes zoster incidence across Europe: results from a systematic literature review. *BMC Infect Dis* 2013;13:170.
- [57] Forbes HJ, Bhaskaran K, Grint D, Hu VH, Langan SM, McDonald HI, et al. Incidence of acute complications of herpes zoster among immunocompetent adults in England: a matched cohort study using routine health data. *Br J Dermatol* 2021;184:1077–84.
- [58] Borkar DS, Tham VM, Esterberg E, Ray KJ, Vinoya AC, Parker JV, et al. Incidence of herpes zoster ophthalmicus: results from the pacific ocular inflammation study. *Ophthalmology* 2013;120:451–6.
- [59] Niederer RL, Meyer JJ, Liu K, Danesh-Meyer HV. Herpes zoster ophthalmicus clinical presentation and risk factors for loss of vision. *Am J Ophthalmol* 2021; 226:83–9.
- [60] Ventura MT, Scichilone N, Paganelli R, Minciullo PL, Patella V, Bonini M, et al. Allergic diseases in the elderly: biological characteristics and main immunological and non-immunological mechanisms. *Clin Mol Allergy* 2017;15:2.
- [61] Miyazaki D, Fukagawa K, Okamoto S, Fukushima A, Uchio E, Ebihara N, et al. Epidemiological aspects of allergic conjunctivitis. *Allergol Int* 2020;69:487–95.
- [62] Leonardi A, Pilego F, Castegnaro A, Lazzarini D, La Gloria Valerio A, Mattana P, et al. Allergic conjunctivitis: a cross-sectional study. *Clin Exp Allergy* 2015;45: 1118–25.
- [63] Ventura MT, D'Amato A, Giannini M, Carretta A, Tummoalo RA, Buquicchio R. Incidence of allergic diseases in an elderly population. *Immunopharmacol Immunotoxicol* 2010;32:165–70.
- [64] Leonardi A, Castegnaro A, Valerio AL, Lazzarini D. Epidemiology of allergic conjunctivitis: clinical appearance and treatment patterns in a population-based study. *Curr Opin Allergy Clin Immunol* 2015;15:482–8.
- [65] Singh S, Donthineni PR, Shanbhag SS, Senthil S, Ong HS, Dart JK, et al. Drug induced cicatrizing conjunctivitis: a case series with review of etiopathogenesis, diagnosis and management. *Ocul Surf* 2022;24:83–92.
- [66] Jung SJ, Mehta JS, Tong L. Effects of environment pollution on the ocular surface.
- [67] Gichuhi S, Sagoo MS, Weiss HA, Burton MJ. Epidemiology of ocular surface squamous neoplasia in Africa. *Trop Med Int Health* 2013;18:1424–43.
- [68] Carreira H, Coutinho F, Carrilho C, Lunet N. HIV and HPV infections and ocular surface squamous neoplasia: systematic review and meta-analysis. *Br J Cancer* 2013;109:1981–8.
- [69] Remberg I. Human papillomavirus-related neoplasia of the ocular adnexa. *Acta Ophthalmol* 2022;100:3–33.
- [70] Höllhumer R, Williams S, Michelow P. Observational study of ocular surface squamous neoplasia: risk factors, diagnosis, management and outcomes at a tertiary eye hospital in South Africa. *PLoS One* 2020;15:e0237453.
- [71] Ka'stelan S, Gverović Antunica A, Beketi'c Ore'sković L, Salopek Rabati'c J, Kasun B, Bakija I. Conjunctival melanoma - epidemiological trends and features. *Pathol Oncol Res* 2018;24:787–96.
- [72] Ghazawi FM, Darwich R, Le M, Jfri A, Rahme E, Burnier JV, et al. Incidence trends of conjunctival malignant melanoma in Canada. *Br J Ophthalmol* 2020; 104:23–5.
- [73] Jain P, Finger PT, Fill M, Damato B, Coupland SE, Heimann H, et al. Conjunctival melanoma treatment outcomes in 288 patients: a multicentre international datasharing study. *Br J Ophthalmol* 2021;105:1358–64.
- [74] Larsen AC. Conjunctival malignant melanoma in Denmark: epidemiology, treatment and prognosis with special emphasis on tumorigenesis and genetic profile. *Acta Ophthalmol* 2016;94:1–27.
- [75] Vaidya S, Dalvin LA, Yaghy A, Pacheco R, Shields JA, Lally SE, et al. Conjunctival melanoma: risk factors for recurrent or new tumor in 540 patients at a single ocular oncology center. *Eur J Ophthalmol* 2021;31:2675–85.
- [76] Virgili G, Parravano M, Gatta G, Capocaccia R, Mazzini C, Mallone S, et al. Incidence and survival of patients with conjunctival melanoma in europe. *JAMA Ophthalmology* 2020;138:601–8.
- [77] Dalvin LA, Yaghy A, Vaidya S, Pacheco RR, Perez AL, Lally SE, et al. Conjunctival melanoma: outcomes based on age at presentation in 629 patients at a single ocular oncology center. *Cornea* 2021;40:554–63.
- [78] Kirkegaard MM, Coupland SE, Prause JU, Heegaard S. Malignant lymphoma of the conjunctiva. *Surv Ophthalmol* 2015;60:444–58.

- [108] Kirkegaard MM, Rasmussen PK, Coupland SE, Esmaeli B, Finger PT, Graue GF, et al. Conjunctival lymphoma—an international multicenter retrospective study. *JAMA Ophthalmology* 2016;134:406–14.
- [109] Sullivan DA, Rocha EM, Aragona P, Clayton JA, Ding J, Golebiowski B, et al. TFOS DEWS II sex, gender, and hormones report. *Ocul Surf* 2017;15:284–333.
- [110] Aninye IO, Digre K, Hartnett ME, Baldonado K, Shriver EM, Periman LM, et al. *Ocul Surf* 2018;16:198–205.
The roles of sex and gender in women's eye health disparities in the United States. *Biol Sex Differ* 2021;12:57.
- [81] Cicinelli MV, Marchese A, Bandello F, Modorati G. Clinical management of ocular surface squamous neoplasia: a review of the current evidence. *Ophthalmol Therap* 2018;7:247–62.
- [82] Darwich R, Ghazawi FM, Le M, Rahme E, Alghazawi N, Zubarev A, et al. Epidemiology of invasive ocular surface squamous neoplasia in Canada during 1992–2010. *Br J Ophthalmol* 2020;104:1368–72.
- [83] Kiire CA, Stewart RMM, Srinivasan S, Heimann H, Kaye SB, Dhillion B. A prospective study of the incidence, associations and outcomes of ocular surface squamous neoplasia in the United Kingdom. *Eye* 2019;33:283–94.
- [84] Kim BH, Kim MK, Wee WR, Oh JY. Clinical and pathological characteristics of ocular surface squamous neoplasia in an Asian population. *Graefes Arch Clin Exp Ophthalmol* 2013;251:2569–73.
- [85] Maudgil A, Patel T, Rundel P, Rennie IG, Mudhar HS. Ocular surface squamous neoplasia: analysis of 78 cases from a UK ocular oncology centre. *Br J Ophthalmol* 2013;97:1520–4.
- [86] McClellan AJ, McClellan AL, Pezon CF, Karp CL, Feuer W, Galor A. Epidemiology of ocular surface squamous neoplasia in a veterans affairs population. *Cornea* 2013;32:1354–8.
- [87] Ramberg I, Heegaard S, Prause JU, Sjø NC, Toft PB. Squamous cell dysplasia and carcinoma of the conjunctiva. A nationwide, retrospective, epidemiological study of Danish patients. *Acta Ophthalmol* 2015;93:663–6.
- [88] Shields CL, Alset AE, Boal NS, Casey MG, Knapp AN, Sugarman JA, et al. Conjunctival tumors in 5002 cases. Comparative analysis of benign versus malignant counterparts. The 2016 James D. Allen lecture. *Am J Ophthalmol* 2017; 173:106–33.
- [89] Fasina O. Ocular surface squamous neoplasia at a tertiary eye facility, Southwestern Nigeria: a 10-year review. *Int Ophthalmol* 2021;41:3325–31.
- [90] Furahini G, Lewallen S. Epidemiology and management of ocular surface squamous neoplasia in Tanzania. *Ophthalmic Epidemiol* 2010;17:171–6.
- [91] Gichuhi S, Macharia E, Kabiru J, Zindamoyen AMB, Rono H, Ollando E, et al. Risk factors for ocular surface squamous neoplasia in Kenya: a case-control study. *Trop Med Int Health* 2016;21:1522–30.
- [92] Meel R, Dhiman R, Vanathi M, Pushker N, Tandon R, Devi S. Clinicodemographic profile and treatment outcome in patients of ocular surface squamous neoplasia. *Indian J Ophthalmol* 2017;65:936–41.
- [93] Pellerano F, Gil G, Rosario A, Mañon N, Vargas T, Vizcaíno G. Survey of 138 conjunctival tumors in the Dominican republic. *Ophthalmic Epidemiol* 2020;27: 278–82.
- [94] Tananuvat N, Niparugs M, Wiwatwongwana D, Lertprasertsuk N, Mahanupap P. Ocular surface squamous neoplasia in Northern Thailand: a 16-year review. *BMC Ophthalmol* 2022;22:121.
- [95] Gichuhi S, Macharia E, Kabiru J, Zindamoyen AM, Rono H, Ollando E, et al. Clinical presentation of ocular surface squamous neoplasia in Kenya. *JAMA Ophthalmology* 2015;133:1305–13.
- [111] Kronzer VL, Bridges Jr SL, Davis 3rd JM. Why women have more autoimmune diseases than men: an evolutionary perspective. *Evolut Appl* 2021;14:629–33.
- [112] Schaumberg DA, Sullivan DA, Buring JE, Dana MR. Prevalence of dry eye syndrome among US women. *Am J Ophthalmol* 2003;136:318–26.
- [113] Schaumberg DA, Dana R, Buring JE, Sullivan DA. Prevalence of dry eye disease among US men. Estimates from the physicians' health studies. *Arch Ophthalmol* 2009;127:763–8.
- [114] Schein OD, Mu'NOz B, Tielsch JM, Bandeen-Roche K, West S. Prevalence of dry eye among the elderly. *Am J Ophthalmol* 1997;124:723–8.
- [115] Racine M, Tousignant-Lafamme Y, Kloda LA, Dion D, Dupuis G, Choiniere M. A systematic literature review of 10 years of research on sex/gender and experimental pain perception - part 1: are there really differences between women and men? *Pain* 2012;153:602–18.
- [116] Li W, Lin MC. Sex disparity in how pain sensitivity influences dry eye symptoms. *Cornea* 2019;38:1291–8.
- [117] Vehof J, Smitt-Kamminga NS, Nibourg SA, Hammond CJ. Sex differences in clinical characteristics of dry eye disease. *Ocul Surf* 2018;16:242–8.
- [118] Uchino M, Dogru M, Yagi Y, Goto E, Tomita M, Kon T, et al. The features of dry eye disease in a Japanese elderly population. *Optom Vis Sci* 2006;83:797–802.
- [119] Hashemi H, Asharous A, Aghamirsalim M, Yekta A, Pourmatin R, Sajjadi M, et al. Meibomian gland dysfunction in geriatric population: tehran geriatric eye study. *Int Ophthalmol* 2021;41:2539–46.
- [120] Lomholt JA, Ehlers N. Graft survival and risk factors of penetrating keratoplasty for microbial keratitis. *Acta Ophthalmol Scand* 1997;75:418–22.
- [121] Magalhaes OA, Marafon SB, Ferreira RC. Gender differences in keratoconus keratoplasty: a 25-year study in Southern Brazil and global perspective. *Int Ophthalmol* 2018;38:1627–33.
- [122] Connor Cgf LL, Hall CW. The influence of gender on the ocular surface. *J Am Optom Assoc* 1999;70:182–6.
- [123] Lahoti S, Weiss M, Johnson DA, Kheirkhah A. Superior limbic keratoconjunctivitis: a comprehensive review. *Surv Ophthalmol* 2022;67:331–41.
- [124] Groessl SA, Sires BS, Lemke BN. An anatomical basis for primary acquired nasolacrimal duct obstruction. *Arch Ophthalmol* 1997;115:71–4.
- [125] Krishnan T, Prajna NV, Gronert K, Oldenburg CE, Ray KJ, Keenan JD, et al. Gender differences in re-epithelialisation time in fungal corneal ulcers. *Br J Ophthalmol* 2012;96:137–8.
- [126] Keita SOY, Kittles RA, Royal CDM, Bonney GE, Furbert-Harris P, Dunston GM, et al. Conceptualizing human variation. *Nat Genet* 2004;36:S17–20.
- [127] Hassanzadeh S, Varmaghani M, Zarei-Ghanavati S, Heravian Shandiz J, Azimi Khorasani A. Global prevalence of meibomian gland dysfunction: a systematic review and meta-analysis. *Ocul Immunol Inflamm* 2021;29:66–75.
- [128] Craig JP, Lim J, Han A, Tien L, Xue AL, Wang MTM. Ethnic differences between the Asian and Caucasian ocular surface: a co-located adult migrant population cohort study. *Ocul Surf* 2019;17:83–8.
191 F. Stapleton et al.
The Ocular Surface 28 (2023) 165–199
- [129] Brown L, Leck AK, Gichangi M, Burton MJ, Denning DW. The global incidence and diagnosis of fungal keratitis. *Lancet Infect Dis* 2021;21:e49–57.
- [130] Fernandes AG, Alves M, Nascimento RAE, Valdrighi NY, de Almeida RC, Nakano CT. Visual impairment and blindness in the xingu indigenous park Brazil. *Int J Equity Health* 2021;20:197.
- [131] Furtado JM, Berezovsky A, Ferraz NN, Mu'noz S, Fernandes AG, Watanabe SS, et al. Prevalence and causes of visual impairment and blindness in adults aged 45 Years and older from parintins: the Brazilian amazon region eye survey. *Ophthalmic Epidemiol* 2019;26:345–54.
- [132] Quinn EK, Massey PD, Speare R. Communicable diseases in rural and remote Australia: the need for improved understanding and action. *Rural Rem Health* 2015;15:3371.
- [133] Foreman J, Keel S, van Wijngaarden P, Bourne RA, Wormald R, Crowston J, et al. Prevalence and causes of visual loss among the indigenous peoples of the world: a systematic review. *JAMA Ophthalmology* 2018;136:567–80.
- [134] Ang M, Li X, Wong W, Zheng Y, Chua D, Rahman A, et al. Prevalence of and racial differences in pterygium: a multiethnic population study in Asians. *Ophthalmology* 2012;119:1509–15.
- [135] Na KS, Mok JW, Kim JY, Joo CK. Proinflammatory gene polymorphisms are potentially associated with Korean non-Sjogren dry eye patients. *Mol Vis* 2011;17: 2818–23.
- [136] He Y, Li X, Bao Y, Sun J, Liu J. [The correlation of polymorphism of estrogen receptor gene to dry eye syndrome in postmenopausal women]. *Eye Sci* 2006;22: 233–6.
- [137] Imbert Y, Foulks GN, Brennan MD, Jumblatt MM, John G, Shah HA, et al. MUC1 and estrogen receptor α gene polymorphisms in dry eye patients. *Exp Eye Res* 2009;88:334–8.
- [138] Imbert Y, Darling DS, Jumblatt MM, Foulks GN, Couzin EG, Steele PS, et al. MUC1 splice variants in human ocular surface tissues: possible differences between dry eye patients and normal controls. *Exp Eye Res* 2006;83:493–501.
- [139] Contreras-Ruiz L, Ryan DS, Sia RK, Bower KS, Dartt DA, Masli S. Polymorphism in THBS1 gene is associated with post-refractive surgery chronic ocular surface inflammation. *Ophthalmology* 2014;121:1389–97.
- [140] Lee L, Garrett Q, Flanagan J, Chakrabarti S, Pappas E. Genetic factors and molecular mechanisms in dry eye disease. *Ocul Surf* 2018;16:206–17.
- [141] Portelli MA, Hodge E, Sayers I. Genetic risk factors for the development of allergic disease identified by genome-wide association. *Clin Exp Allergy* 2015;45:21–31.
- [142] Kumar S. Vernal keratoconjunctivitis: a major review. *Acta Ophthalmol* 2009;87.
- [159] Magno MS, Utheim TP, Snieder H, Hammond CJ, Vehof J. The relationship between dry eye and sleep quality. *Ocul Surf* 2021;20:13–9.
- [160] Galor A, Seiden BE, Park JJ, Feuer WJ, McClellan AL, Felix ER, et al. The association of dry eye symptom severity and comorbid insomnia in US veterans. *Eye Contact Lens* 2018;44(Suppl 1): S118–s24.
- [161] Yu X, Guo H, Liu X, Wang G, Min Y, Chen SS, et al. Dry eye and sleep quality: a large community-based study in Hangzhou. *Sleep* 2019;42.
- [162] Bitar MS, Olson DJ, Li M, Davis RM. The correlation between dry eyes, anxiety and depression: the sicca, anxiety and depression study. *Cornea* 2019;38:684–9.
- [163] Um SB, Yeom H, Kim NH, Kim HC, Lee HK, Suh I. Association between dry eye symptoms and suicidal ideation in a Korean adult population. *PLoS One* 2018;13: e0199131.
- [164] Stapleton F, Shrestha GS, Vijay AK, Carnt N. Epidemiology, microbiology, and genetics of contact lens-related and non-contact lens-related infectious keratitis. *Eye Contact Lens* 2022;48:127–33.
- [165] Sobol EK, Fargione RA, Atiya M, Diaz JD, Powell JA, Gritz DC. Case-control study of herpes simplex eye disease: bronx epidemiology of human immunodeficiency virus eye studies. *Cornea* 2016;35:801–6.
- [166] Rosenberg CR, Abazari A, Chou TY, Weissbart SB. Comparison of comorbid associations and ocular complications in herpes simplex and zoster keratitis. *Ocul Immunol Inflamm* 2022;30:57–61.
- [167] Jeng BH, Gritz DC, Kumar AB, Holsclaw DS, Porco TC, Smith SD, et al. Epidemiology of ulcerative keratitis in northern California. *Arch Ophthalmol* 2010;128:1022–8.

Cosmetics: Time to come clean

By JCP Roos, A Gallant Sullivan and R Murthy

The cosmetics industry is everywhere – we are confronted by glossy lips on glossy magazines, and mesmerizing eyes which dazzle with applied products. What may be less obvious is that the cosmetics industry also enters the medical consultation room of eye specialists who deal with the tear film and ocular surface.

The tear film may not sound important, but it is the key ingredient responsible for sharp vision and comfortable eyes. But at the moment the tear film is under assault and needs your help.

A recent scientific report has linked lifestyle choices with degradation in the tear film, which can prevent contact lens wear, cause irritation and leave us with watering eyes at work or outside. Our lifestyle choices include where we live, where we work, how we commute, what we eat and how we spend our free time. But it also includes what we apply to our skin. Cosmetics are one of the most frequently discussed subjects in ocular surface clinics as women, men & our children use more cosmetics and skincare, and if it isn't, it should be.

The pursuit of beautification began more than 4000 years ago – long before Cleopatra - and has never abated. Today, a woman in the United States applies twelve cosmetic products a day, and a man uses six; 60% of women in the United States apply mascara at least eight times per week.

Many of the ingredients in mainstream cosmetics are unregulated and known to contain toxic chemicals. In fact, over 12,000 chemicals are used in these formulations and less than 20% have been proven safe, and specifically not proven eye safe. Once absorbed through the skin, these chemical agents may act as neurotoxins, endocrine disruptors and reproductive toxins, and may exacerbate or promote the development of ocular surface and adnexal disease². One useful website for understanding ingredients in cosmetics is www.incodecoder.com. Recent research has demonstrated that there are multiple adverse reactions to eye cosmetics, including irritation, keratitis, allergies, eyelid dermatitis, meibomian gland, corneal and conjunctival epithelial cell toxicity, dry eye disease, and peri-ocular atrophy.

Education and knowledge are key to making informed lifestyle choices and provided the impetus for The Tear Film & Ocular Surface Society's (TFOS: tearfilm.org) global workshop report "**A Lifestyle Epidemic: Ocular Surface Disease**". The 3-year effort, headed by Dr. David Sullivan, engaged 158 experts from 38 countries around the world to achieve a scientific consensus concerning lifestyle choices and their impact on ocular surface disease.

One subcommittee focused on the use of eye cosmetic products, their history and market value, psychological and social impacts, possible problems associated with cosmetic ingredients, products, and procedures, and regulations for eye cosmetic use. Additionally, there was a systematic review that critically appraised randomized controlled trial evidence concerning the ocular effects of eyelash growth products.



1. Establish the diagnosis and exclude underlying systemic conditions.

- Use tools such as: Slit Lamp Biomicroscopy; Quantitative tear film analysis and Meibomography; and VISIA skin analysis

2. Treat with innovative therapeutics.

- Use tools such as: Intense pulsed light (IPL) treatments for DED, MGD, and skin rosacea

3. Advise at-home protocols for in-between treatments.

- Integrate eye-safe products into your patients' daily routines, from Purifeyes microbiome protection, a novel hypochlorous developed to be ocular surface compatible, to Èyes Are The Story optocosmetics

4. Review and add in oral therapies, or office procedures as required.

Relatively few consumers are aware of the ocular hazards of cosmetics and we must now learn from this report to help us educate eye care providers and consumers about the risks associated with cosmetics and application techniques.

In the past the mainstay of treatment of ocular surface disease was symptom relief with lubricating eye drops, topical creams and oral medications. The effectiveness of these were limited by side effects and poor compliance. The role of aesthetic treatments and cosmetics were rarely considered, if at all. One holistic approach to dry eye care is the OptimEyes™ program created by Drs. Rachna Murthy and Jonathan Roos in London and Cambridge.

“As ophthalmologists and aesthetic eyelid surgeons we now integrate eye-safe products into our patients’ daily home routines, from microbiome protection with the eye-safe spray Purifeyes (purifeyes.co.uk) and with *Èyes Are The Story optocosmetics*.” explained Rachna Murthy. This is coupled with state of the art Optilight™ by Lumenis treatment to enhance meibomian gland function and reduce rosacea.

The TFOS Report is now a must-read for all eye care professionals needing to understand and explain how our choices impact our eyes, our vision, and our quality of life.




i Envntl. Working Grp., Exposures Add Up- Survey Results (2004), <http://www.ewg.org/skindeep/2004/06/15/exposures-add-up-survey-results/>.

ii Sullivan DA, da Costa AX, Del Duca E, Doll T, Grupchev CN, Lazreg S, Liu SH, McGee SR, Murthy R, Narang P, Ng A, Nistico S, O'Dell L, Roos J, Shen J, Markoulli M. TFOS lifestyle: Impact of cosmetics on the ocular surface. *The Ocular Surface*, 2023, in press.

OSI Symposium Testimonial

Nevien Lotfy Abdelkader



“I had the absolute pleasure of attending the OSI symposium and dry eye masterclass, and as someone who is deeply focused on the Cornea, it was a golden opportunity to enrich my knowledge in so many aspects.

What set this two-day symposium apart was the outstanding presentations from numerous eminent speakers, who conveyed their expertise through real-life clinical experiences that cannot be found in literature.

The Dry Eye Masterclass was comprised of 7 workshops, which provided a hands-on experience that enabled participants to witness the hows and know-tos for themselves. The open discussions that followed were particularly useful, leading to productive and interactive sessions.

In summary, my experience was incredibly fruitful, diverse, and friendly to young ophthalmologists.”



GLAUCOMA

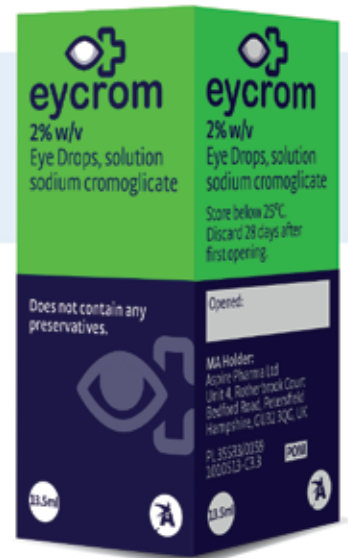
ANTI-INFECTIVE

ANTI-INFLAMMATORY

ANTI-ALLERGY

Reducing the burden of ophthalmic prescribing[†]

- Preservative free solutions¹
- Precision multi-dose devices²
- Patient-centric designs^{2,3}
- Established molecules¹



For more information visit www.eyrange.co.uk



Eycrom (sodium cromoglicate 2% w/v eye drops) Prescribing Information:

Indication: For the prophylaxis and symptomatic treatment of acute allergic conjunctivitis, chronic allergic conjunctivitis and vernal keratoconjunctivitis. **Dosage:** One or two drops in each eye four times a day. Children may require supervision/assistance. **Adverse reactions:** Transient stinging and burning may occur after instillation. Consult SmPC for other adverse reactions. **Contraindications:** Hypersensitivity to any ingredient. **Precautions:** Discard four weeks after opening. Remove contact lenses prior to instillation- may be reinserted 15 minutes after administration. Do not use if history of contact hypersensitivity to silver. Advice should be sought before discontinuing product. **Pregnancy:** Only use in pregnancy where there is a clear need. **Driving:** Do not drive if vision blurred. **Legal Classification:** POM **Cost:** £8.03 - 13.5 ml dropper bottle **MA number:** PL 35533/0159, **MAH:** Aspire Pharma, Unit 4, Rotherbrook Court, Bedford Road, Petersfield, GU32 3QG. **Date reviewed:** March 2023. **Version Number:** 10105131120 v 3.0.

References: 1. Eycrom (sodium cromoglicate) Summary of Product Characteristics. 2. Novelia® PureFlow Technology. <https://www.nemera.net/products/ophthalmic/novelis/> (Accessed March 2023). 3. Novelia® PureFlow Technology. <https://www.nemera.net/knowledge-hub/the-pivotal-role-played-by-device-developers-to-improve-patient-eye-care/> (Accessed March 2023).

Based on EY bottles vs UDVs[†]

1010461587 v 7.0 March 2023

Adverse events should be reported.
Reporting forms and information can be found at www.mhra.gov.uk/yellowcard.
Adverse events should also be reported to Aspire Pharma Ltd on 01730 231148.

Effect of maqui-berry extract in dry eye disease – A clinical and molecular analysis



Gairik Kundu, Rohit Shetty, Sharon D'Souza, Bhavya Gorimanipalli, Ameeta Koul and Swaminathan Sethu¹

Purpose: This study aims to investigate the effects of maqui-berry extract (MBE) in improving signs and symptoms of dry eye disease (DED) along with ocular surface inflammation in patients with DED. **Methods:** Twenty patients were randomly assigned to a MBE or a placebo group (PLC). DED parameters including Schirmer's test 1 (ST1), tear film break-up time (TBUT), ocular surface disease index (OSDI), and corneal staining were assessed before treatment and 2 months post-treatment. Tear fluid samples before and after treatment from a subset of these patients were collected from the study subjects using sterile Schirmer's strips, and the levels of interleukin (IL)-1 β , IL-10, IL-6, IL-17A, tumor necrosis factor- α (TNF α), matrix metalloproteinase-9 (MMP9), soluble intercellular adhesion molecule-1 (sICAM1), and vascular endothelial growth factor-A (VEGF-A) were measured using a microfluidic cartridge-based multiplex ELISA. **Results:** The MBE group demonstrated a significant ($p < 0.05$) decrease in OSDI scores along with a significant increase in Schirmer's test 1 compared to the PLC group. No significant change in TBUT and corneal staining was observed between the study groups. Levels of proinflammatory factors such as IL-1 β , IL-6, IL-17A, TNF α , and MMP9 were observed to be significantly reduced, along with a significant increase in IL-10 levels following treatment in the MBE group compared with the PLC group. **Conclusion:** Consumption of MBE resulted in the resolution of DED signs and symptoms, along with a reduction in ocular surface inflammation.

Dry eye disease (DED) is a multifactorial condition with a complicated etiopathogenesis and is often broadly divided into insufficient tear production and excessive tear evaporation and with both.^[1] Irrespective of the underlying causative conditions, DED is associated with ocular surface inflammation.^[1] The role of conventional pharmacological treatment which includes lubricating topical formulations and immunomodulators is well known; however, there may be other mechanisms to reduce ocular surface inflammation.^[2] Some patients do not respond well to currently available therapies, and hence newer strategies do become necessary. Maqui berry (*Aristotelia chilensis*) which is grown in the Patagonia region of Chile is rich in anthocyanins and has been used traditionally to treat inflammation in various parts of the body.^[3,4] Delphinidin-3,5-O-diglucoside is a specific compound in maqui berries.^[3,4] Anthocyanins in maqui berry are delphinidin derivatives with antioxidant activities and, thus, anti-inflammatory in nature.^[3,4] The possible anti-inflammatory effect could also be explained due to the inhibitory effect of delphinol on NF κ B activation, which is responsible for the production of proinflammatory factors.^[5] An animal study demonstrated that the consumption of maqui berry inhibited the decline in lacrimal fluid production and prevented damages to corneal and lacrimal gland tissues in a DED animal model.^[6] Additionally, it has also been

demonstrated to increase tear production, thereby improving overall DED-related symptoms in a previous human pilot study.^[7] Owing to the lack of a placebo group in the pilot trial, the evidence related to the beneficial effects of maqui berry on tear production and alleviation of DED signs and symptoms remains insufficient. Hence, this study was conducted to investigate the effects of maqui-berry extract (MBE) on DED clinical parameters and ocular surface inflammation in patients with DED.

Methods

Study cohort and design

The study was a prospective interventional study which was undertaken in a tertiary care eye hospital in India, between July 2022 and September 2022. The study was approved by the institutional ethics committee. The study followed the tenets of the Declaration of Helsinki. The selection criteria of this study were as follows: (a) patients aged 30–50 years; (b) presence of eye dryness symptoms; with ocular surface disease index (OSDI) >18 , tear film break-up time (TBUT) ≤ 10 but ≥ 5 s, with Schirmer's test 1 (ST1) value ≤ 10 mm/5 min but ≥ 5 mm/5 min. The exclusion criteria included patients diagnosed with severe dry eye syndrome with Schirmer 1 $< 5/5$ min, taking any medication for DED (provided that a patient has not taken the medication for 4 weeks before the study and does not take the medication during the study period), current eye disease or a history of eye disease, currently using eye drops for the treatment of any eye diseases, previous corneal surgeries, presence of Sjögren's syndrome, allergy, or chronic asthma, allergies to medications and/or products related to the study substance; pregnancy, lactation. Prohibited medications during the study were topical cyclosporine or any other ophthalmic medication, including artificial tears, antihistamines, corticosteroids, or mast cell stabilizers.

Of the 20 patients recruited, 12 patients (24 eyes) were randomized into the group which received MBE in the form of tablets (MaquveTM-Lavue pharmaceuticals), and 8 patients (16 eyes) were randomized into the placebo group (PLC). The mean age in the MBE group was 35 ± 3.4 years with 67% males and 33% females. The mean age in the PLC group was 34 ± 4.2 years with 63% males and 37% females. The supplements given were indistinguishable brown capsules containing MBE or placebo. The capsules were approved as identical to each other in color, odor, and flavor, although active capsules contained 120 mg of dextrin and

30 mg of MBE in powder containing up to 10.5 mg of total anthocyanins, up to 7.5 mg of total delphinidins, and delphinidin-3,5-O-diglucoside, while placebo capsules were inert gelatin capsules which contained 180 mg of dextrin and did not induce inflammation. All patients were administered one capsule twice per day either with MBE or placebo before food in the morning and night for 4 weeks followed by one capsule once daily in the morning before food for 4 weeks. The study follow-up was divided into pretreatment initiation and 2 months postinitiation of treatment.

Clinical parameters

Ocular surface and dry eye evaluation include the assessment of symptoms using the OSDI questionnaire (Allergan, Dublin, Ireland)^[8] Schirmer's test without anesthesia (ST1), TBUT, and corneal fluorescein staining. Schirmer's test 1 was performed using sterile Schirmer's strips (Contacare Ophthalmics and Diagnostics, Vadodara, Gujarat, India). TBUT and ocular surface staining were performed using fluorescein strips (Contacare Ophthalmics and Diagnostics). Objective and subjective measures were done at baseline visit, and 2 months post initiation of treatment. Objective assessments also included Schirmer's test without anesthesia (ST1), TBUT, corneal fluorescein score. Subjective assessments included the OSDI questionnaire to measure ocular discomfort.^[8,9] In addition, tear fluid samples were collected from a subset of patients which included 12 eyes of the MBE group and 8 eyes of the PLC group at baseline and 2 months to measure the concentration of tear-soluble factors.

Tear fluid sample collection

Tear fluid samples before and after treatment were collected from the study subjects using sterile Schirmer's strips (Contacare Ophthalmics and Diagnostics, Vadodara, Gujarat, India) by following Schirmer's test 1 protocol. Following the wetting of the Schirmer's strip by the tear fluid, the wetting length was

noted and the Schirmer's strip was then stored in a sterile microcentrifuge tube at -80°C until further processing.

Tear soluble factor measurements in the clinics

The levels of interleukin (IL)-1 β , IL-10, IL-6, IL-17A, tumor necrosis factor- α (TNF α), matrix metalloproteinase 9 (MMP9), soluble intercellular adhesion molecule 1 (sICAM1), and vascular endothelial growth factor-A (VEGF-A) were measured in the tear fluid samples collected using a microfluidic cartridge-based multiplex ELISA kit (Bio-M Pathfinder, NovoMol-Dx, India, a customized version of the EllaTM Automated ELISA system, Bio-Techne[®] Corporation, Minnesota, USA). Briefly, 300 μl of extraction buffer was added to the microcentrifuge tube containing the Schirmer's strip and was agitated for 5 min at room temperature. Subsequently, 50 μl of the eluted tear sample was added to the sample well, and 1 ml of wash buffer was put into the buffer well in the kit's cartridge. The cartridge was then placed into the device, and a run was initiated. At the end of the run, the absolute concentration of the specific factors was determined based on the standard curve which was built into the cartridge. The Schirmer's strip wetting length for the respective sample and extraction buffer volume was used to adjust the absolute concentration to determine to final concentration for the specific factors for every sample.

Statistical analysis

The normal distribution of the data was determined by the Shapiro-Wilk normality test. The statistical significance between matched data of pre-treatment and post-treatment parameters was analyzed by the Wilcoxon matched-pairs signed rank test. The statistical significance between the treatment groups for the various parameters was analysed by Mann Whitney test. P value <0.05 was considered to be statistically significant.

Results

The eyes of the study subjects on MBE tablets – MBE showed improvement in some of the dry eye parameters compared to the eyes of subjects on placebo tablets – PLC. [Figs. 1–3]. The OSDI score was observed to be significantly decreased post-treatment compared to pre-treatment scores in the eyes of subjects on MBE [Fig. 1a]. No significant difference in the OSDI score was observed between pre- and post-treatment in the PLC group [Fig. 1a]. A higher proportion (75%) of eyes of subjects on MBE treatment showed a reduction in the OSDI scores following treatment, whereas 25% of the eyes of subjects showed a reduction in the OSDI scores following PLC treatment [Fig. 2a]. The fold difference in the OSDI score between pre- and post-treatment was significantly lower in the MBE-treated group compared to the PLC group [Fig. 3a]. Schirmer's test 1 (ST1) value was observed to be significantly increased post-treatment compared to pre-treatment scores in the eyes of subjects on MBE [Fig. 1b]. No significant difference in the ST1 was observed between pre- and post-treatment ST1 values in the PLC group [Fig. 1b]. A higher proportion (67%) of eyes of subjects on MBE treatment showed an increase in ST1 values following treatment, whereas none of the eyes of subjects showed an increase in ST1 values following PLC treatment [Fig. 2b]. The fold difference in the increase in ST1 values pre- and post-treatment was significantly higher in the MBE-treated group compared to the PLC group [Fig. 3b].

No significant improvement or changes in the TBUT [Figs. 1c and 3c] and staining score [Figs. 1d and 3d] were observed following treatment compared to pre-treatment values in both MBE and PLC groups.

Tear fluid samples were collected to assess tear inflammatory factor levels from the study subjects before and after the treatment with MBE or PLC. The levels of pro-inflammatory factors such as IL-1 β , IL-6, IL-17A, and TNF α were observed to be significantly reduced following treatment with MBE compared to pre-treatment levels [Fig. 4]. It is noteworthy that an anti-inflammatory factor, IL-10, was observed to be significantly increased following treatment with MBE compared to pre-treatment levels [Fig. 4]. On the other hand, an increase in the levels of IL-1 β , IL-6, IL-17A, TNF α , MMP9, and sICAM1 was observed in the post-treatment tear samples compared to pre-treatment samples in the PLC group [Fig. 4]. The fold difference in the levels of IL-1 β , IL-6, IL-17A, TNF α , MMP9, and VEGF between pre- and post-treatment was significantly lower in the MBE-treated group compared to the PLC group [Fig. 5].

The fold difference in the levels of IL-10 between pre- and post-treatment was significantly higher in the MBE-treated group compared to the PLC group [Fig. 5].

Figure 1: Effect of maqui-berry extract (MBE) treatment on OSDI score, TBUT, Schirmer's test 1, and staining score in study subjects. The box and whiskers plots indicate minimum, first quartile, median, third quartile, and maximum values of the OSDI score (a), Schirmer's test 1 – ST1 values (b), tear break up time – TBUT (c), and staining score (d) before (pre-Rx) and after (post-Rx) treatment from subjects under MBE or under placebo (PLC) treatment. MBE – 24 eyes; PLC – 16 eyes. **p < 0.01; Wilcoxon matched-pairs signed rank test

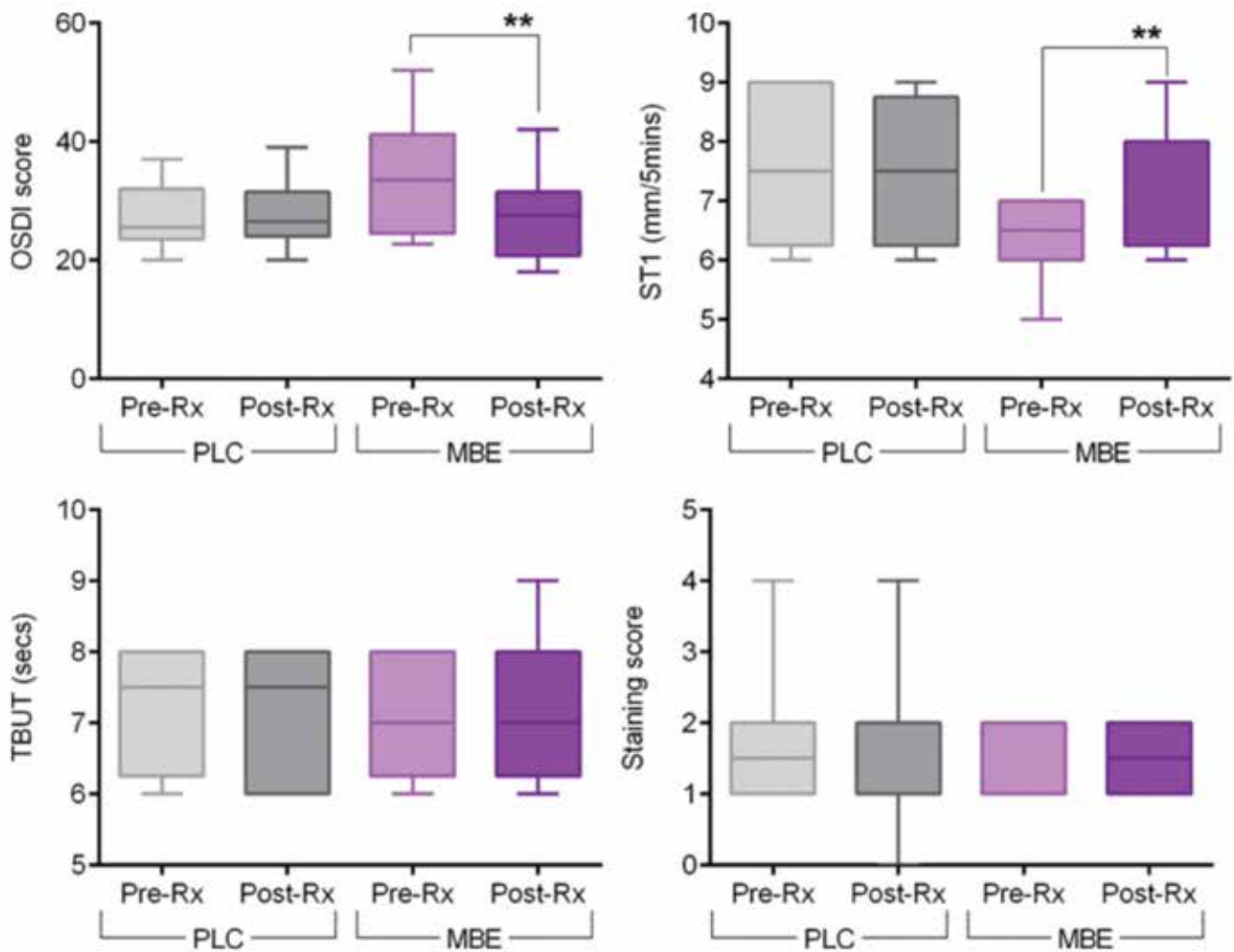
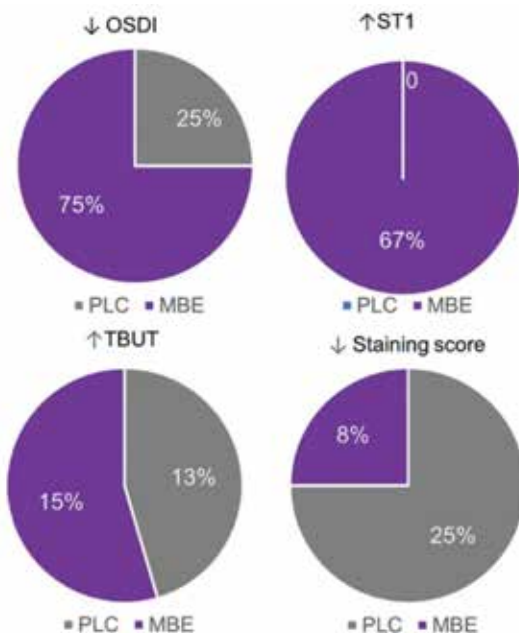


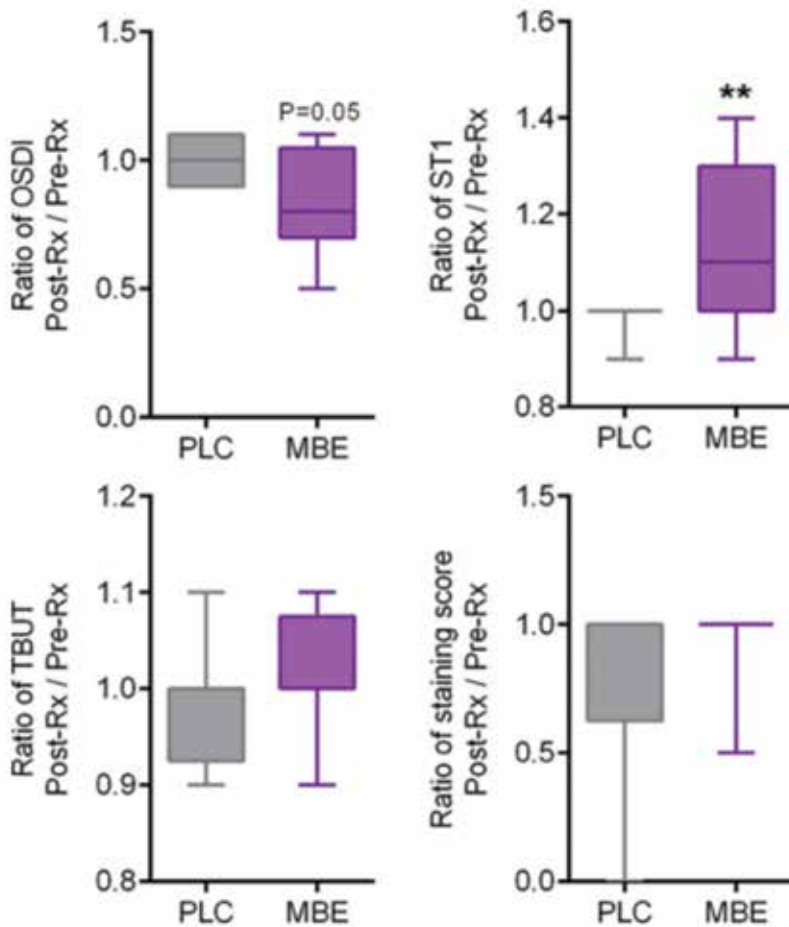
Figure 2: Proportion of eyes that exhibited beneficial changes in OSDI score, TBUT, Schirmer's test 1, and staining score in study subjects following placebo or maqui-berry extract treatment (MBE). The pie charts indicate the percentage of eyes that showed a decrease in OSDI score (a), increase in Schirmer's test 1 – ST1 values (b), decrease in tear break up time – TBUT (c), and decrease in staining score (d) after treatment compared to pretreatment values in subjects under MBE or under placebo (PLC) treatment



Discussion

This study looked at the effect of the consumption of a standardized MBE on DED parameters. The results showed a significant increase in tear production and resolution in ocular surface discomfort. There have been several studies which have demonstrated the consumption of maqui berry in animal models and humans. Nakamura et al.^[6] showed the oral administration of a MBE stabilized the lacrimation secretion resulting from dry air and partial damage to the cornea and lacrimal gland tissue in vitro. Hitoe et al.^[7] suggested that the intake of both 30 and 60 mg/day of MBE considerably enhanced the amount of tear fluid after 4 and 8 weeks in humans with DED. They concluded that an increase in the lacrimal fluid could be stimulated by delphinidin-3,5-O-diglucoside in MBE, a compound known to inhibit the production of reactive oxygen species (ROS) in the lacrimal gland tissue and known to suppress lacrimal gland tissue dysfunction, thereby preventing DED-related symptoms.^[7,10]

Figure 3: *Fold changes in OSDI score, TBUT, Schirmer's test 1, and staining score in study subjects following placebo or maqui-berry extract treatment (MBE). The box and whiskers plots indicate minimum, first quartile, median, third quartile, and maximum fold difference or ratio of the OSDI score (a), Schirmer's test 1 –ST1 values (b), tear break up time – TBUT (c), and staining score (d) following treatment in subjects under MBE compared to those under placebo (PLC) treatment. The ratio of change or fold difference for each of the parameters was determined by dividing the post-treatment values by the pre-treatment value for every study subject. MBE – 24 eyes; PLC – 16 eyes. **p < 0.01; Mann–Whitney test*



Based on the OSDI questionnaire in this study, MBE intake alleviated subjective symptoms associated with DED like what was seen in our study where patients in the MBE group had a significant reduction in OSDI.^[7] OSDI results are consistent with those of the previous MaquiBright® pilot trial and demonstrated improvement in ocular symptoms.^[7] In addition, there was also a reduction in subjective symptoms associated with eye fatigue/discomfort, demonstrating that MBE alleviated ocular surface discomfort and dry eye-related symptoms. The rise in tear secretion observed by the consumption of MBE probably reduced general subjective symptoms associated with DED.

Many studies investigating the onset mechanism of dry eyes have attributed the condition not only to lacrimal dysfunction but also to external factors such as a decrease in blinking, computer and visual display terminal use, and several other factors.^[11-14] An increase in ROS causes inflammation in corneal epithelial cells, which, in turn, decreases the stability of the tear film layer.^[15] Some animal studies have confirmed a reduction of blinking frequency in animals with dry eyes, further augmenting ROS production and the presence of ROS in the tear film.^[16,17] Hence, the consumption of MBE, a botanical extract with antioxidant properties, causes an increase in the amount of lacrimal fluid, with a reduction of ROS formation in the lacrimal gland tissue, and an improvement in the subjective symptoms of eye discomfort and fatigue.^[17]

Although the consumption of MBE increased the amount of tear fluid based on the results of the Schirmer's test, no significant changes were observed in the TBUT. This lack of effect might have resulted from different underlying etiology as aqueous deficient and evaporative, and both differ in the underlying mechanism of the onset.^[18] Although participants in this study might not have had significant evaporative dry eyes, the Schirmer's test results revealed that their tear fluid quantity was between 5 and 10 mm/5 min and TBUT was between 5 and 10 s, which is still lower than normal (moderate evaporative eye dryness). Thus, the effect of MBE intake on the TBUT time was not statistically significant. Therefore, further studies on the role of MBE are needed to investigate TBUT in patients experiencing excessive evaporative DED.

This is the first study to look at tear inflammatory factor levels following the use of MBE, and the levels of pro-inflammatory factors such as IL-1 β , IL-6, IL-17A, TNF α , and MMP9 were observed to be significantly reduced following treatment with MBE compared to pretreatment levels. The reduction observed in the inflammatory cytokines on the ocular surface could possibly be due to the inhibitory effect of delphinol on NF κ B activation, a key transcription factor responsible for the production of proinflammatory factors.^[5,19] We, therefore, speculate that the patients with DED might be experiencing eye pain or discomfort-related symptoms or abnormal nociceptive response due to disruption in the pro- and antinociceptive factor balance on the ocular surface and MBE seems to be reducing these

proinflammatory/ nociceptive cytokines. IL-1 β , a major proinflammatory cytokine, activates nociceptors to generate action potentials and induces pain on the ocular surface.^[20] IL-17A, a key factor in inflammatory disorders, is also involved in nociception as its receptors are expressed by nociceptor neurons.^[21] Interestingly, IL-10, which has been documented for its potent antinociceptive function and has been harnessed in the management of pain,^[22] is an anti-inflammatory cytokine which was observed to be significantly increased following treatment with MBE, highlighting an important anti-inflammatory property in addition to increase in tear levels.

The limitation was a smaller sample size and that we did not include patients who had severe DED as these patients could not be stopped on topical medications to assess the efficacy. Also, the cohort of patients selected were restricted not to only aqueous deficiency DED on which MBE is known to act on but also included both evaporative and aqueous deficiency (mixed dry eye). MBE influences increased the tear fluid generation and diminished subjective symptoms of eye fatigue/discomfort, along with a potent anti-inflammatory effect on the ocular surface. Thus, future studies should be done to investigate the impact of MBE on eye dryness, in a larger cohort of patients with possible additive effects to existing topical medications across grades of DEDs, and this can provide clinicians with an important new oral medication with a unique mechanism of action in DED.

Figure 4: *Effect of maqui-berry extract (MBE) treatment on the tear soluble factor levels in study subjects. The box and whiskers plots indicate minimum, first quartile, median, third quartile, and maximum values of the IL-1 β , IL-6, IL-17A, TNF α , MMP9, sICAM1, VEGF, and IL-10 levels in the tear samples collected before (pre-Rx) and after (post-Rx) treatment from subjects under MBE or under placebo (PLC) treatment. MBE – 12 eyes; PLC – 8 eyes. **p < 0.01, Wilcoxon matched-pairs signed rank test; Dp < 0.05, Mann-Whitney test. IL – interleukin, tumor necrosis factor- α (TNF- α), matrix metalloproteinase-9 (MMP-9), soluble intercellular adhesion molecule-1 (sICAM-1), and vascular endothelial growth factor-A (VEGF-A)*

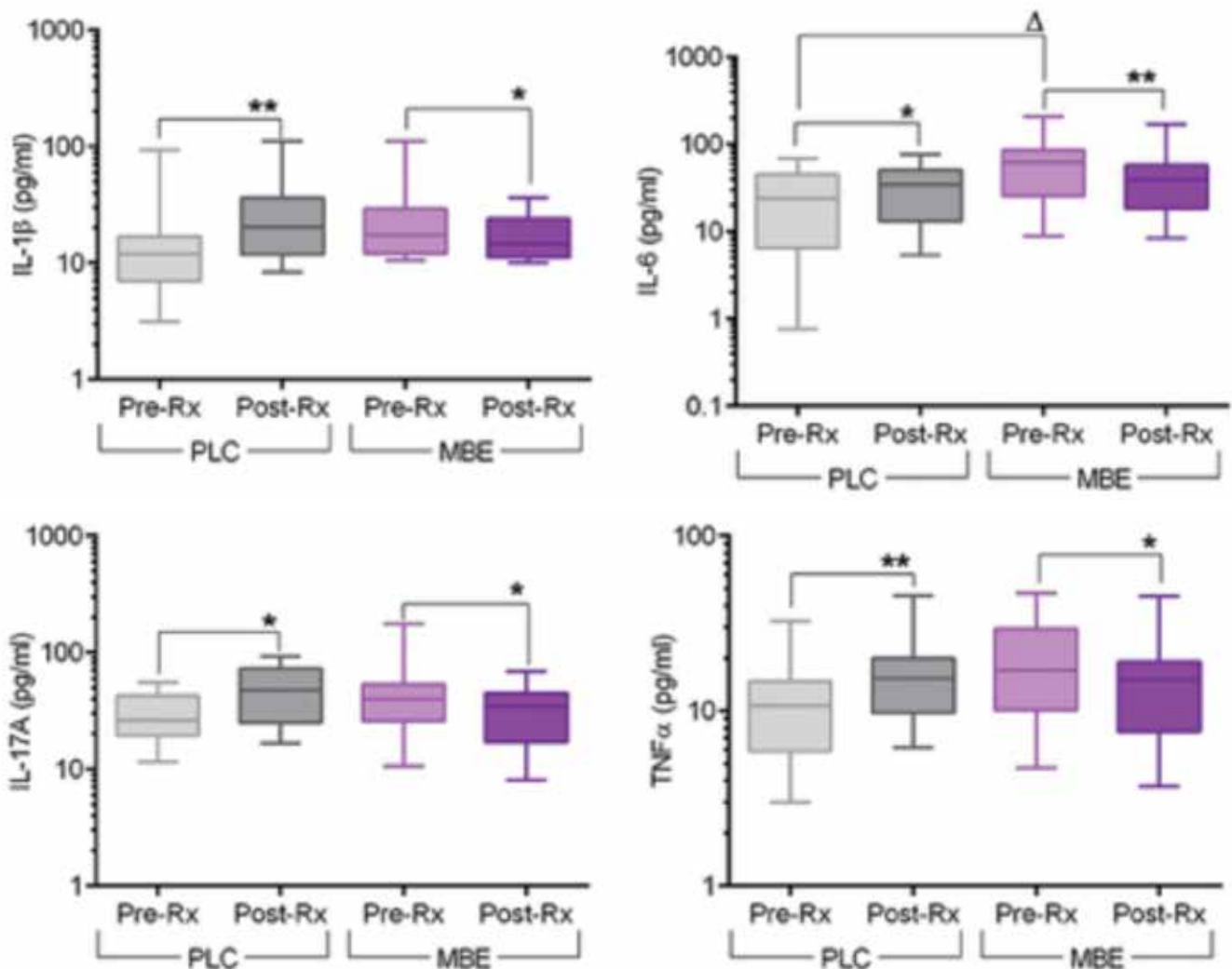
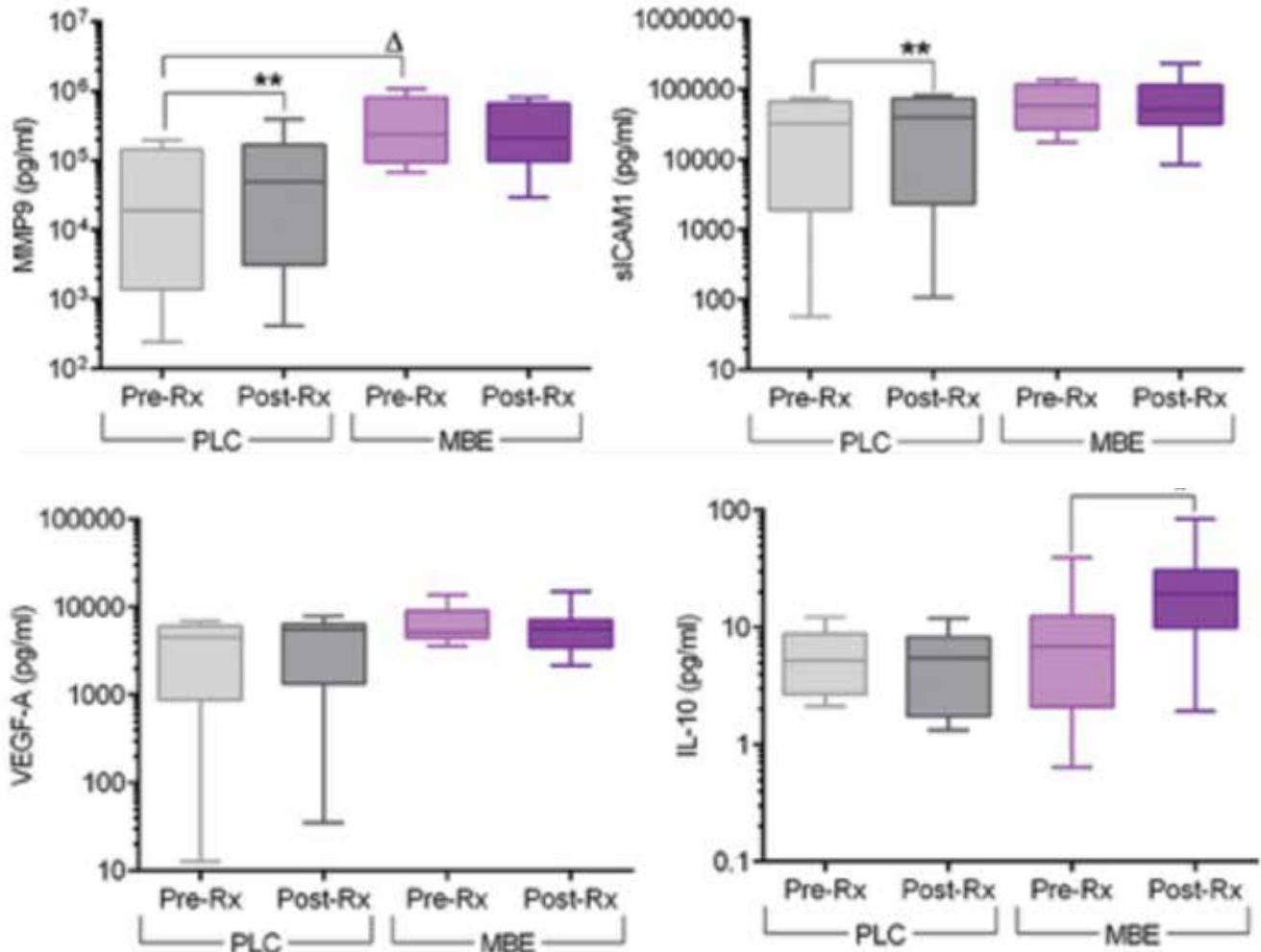


Figure 5: Fold changes in tear soluble factors in study subjects following placebo or maqui-berry extract treatment (MBE). The box and whiskers plots indicate minimum, first quartile, median, third quartile, and maximum fold difference or ratio of IL-1 β , IL-6, IL-17A, TNF α , MMP9, sICAM1, VEGF, and IL-10 levels following treatment in subjects under MBE treatment compared to those under placebo (PLC) treatment. The ratio of change or fold difference for each of the soluble factor's concentrations was determined by dividing the post-treatment values by the pretreatment value for every study subject. MBE – 12 eyes; PLC – 8 eyes. ** $p < 0.01$, *** $p < 0.001$, **** $p < 0.0001$, Mann-Whitney test. IL – interleukin, tumor necrosis factor- α (TNF- α), matrix metalloproteinase-9 (MMP-9), soluble intercellular adhesion molecule-1 (sICAM-1), and vascular endothelial growth factor-A (VEGF-A)



Conclusion

Thus, consumption of maqui-berry extract resulted in significant improvement of DED signs and symptoms, along with a reduction in ocular surface inflammation based on tear biomarker profiling. It can prove to be a useful addition to existing treatment options in the form of oral supplementation in patients with dry eye disease to enhance and improve the ocular surface health.

Financial support and sponsorship

Nil.

Conflicts of interest

There are no conflicts of interest.

References:

1. Craig JP, Nelson JD, Azar DT, Belmonte C, Bron AJ, Chauhan SK, et al. TFOS DEWS II report executive summary. *Ocul Surf* 2017;15:802-12.
2. Jones L, Downie LE, Korb D, Benitez-Del-Castillo JM, Dana R, Deng SX, et al. TFOS DEWS II management and therapy report. *Ocul Surf* 2017;15:575-628.
3. Misle E, Garrido E, Contardo H, González W. Maqui [Aristotelia chilensis (Mol.) Stund]-the amazing chilean tree: A review. *J Agric Sci Technol* 2011;1:473-82.
4. Muñoz O, Christen P, Cretton S, Backhouse N, Torres V, Correa O, et al. Chemical study and anti-inflammatory, analgesic and antioxidant activities of the leaves of *Aristotelia chilensis* (Mol.) Stund, Elaeocarpaceae. *J Pharm Pharmacol* 2011;63:849-59.
5. Krum SA, Chang J, Miranda-Carboni G, Wang CY. Novel functions for NFκB: Inhibition of bone formation. *Nat Rev Rheumatol* 2010;6:607-11.
6. Nakamura S, Tanaka J, Imada T, Shimoda H, Tsubota K. Delphinidin 3,5-O-diglucoside, a constituent of the maqui berry (*Aristotelia chilensis*) anthocyanin, restores tear secretion in a rat dry eye model. *J Funct Foods* 2014;10:346-54.
7. Hito S, Tanaka J, Shimoda H. MaquiBright™ standardized maqui berry extract significantly increases tear fluid production and ameliorates dry eye-related symptoms in a clinical pilot trial. *Panminerva Med* 2014;56 (3 Suppl 1):1-6.
8. Wolffsohn JS, Arita R, Chalmers R, Djalilian A, Dogru M, Dumbleton K, et al. TFOS DEWS II diagnostic methodology report. *Ocul Surf* 2017;15:539-74.
9. Miller KL, Walt JG, Mink DR, Satram-Hoang S, Wilson SE, Perry HD, et al. Minimal clinically important difference for the ocular surface disease index. *Arch Ophthalmol* 2010;128:94-101.
10. Tanaka J, Kadekaru T, Ogawa K, Hito S, Shimoda H, Hara H. Maqui berry (*Aristotelia chilensis*) and the constituent delphinidin glycoside inhibit photoreceptor cell death induced by visible light. *Food Chem* 2013;139:129-37.
11. Tsubota K, Nakamori K. Dry eyes and video display terminals. *N Engl J Med* 1993;328:584.
12. Tsubota K, Toda I, Nakamori K. Poor illumination, VDTs, and desiccated eyes. *Lancet* 1996;347:768-9.
13. Schlote T, Kadner G, Freudenthaler N. Marked reduction and distinct patterns of eye blinking in patients with moderately dry eyes during video display terminal use. *Graefes Arch Clin Exp Ophthalmol* 2004;42:306-12.
14. Wolkoff P, Nojgaard JK, Troiano P, Piccoli B. Eye complaints in the office environment: Precorneal tear film integrity influenced by eye blinking efficiency. *Occup Environ Med* 2005;62:4-12.
15. Augustin AJ, Spidnas M, Kaviani N, Meller D, Koch FH, Grus F, et al. Oxidative reactions in the tear fluid of patients suffering from dry eyes. *Graefes Arch Clin Exp Ophthalmol* 1995;233:694-8.
16. Nakamura S, Shibuya M, Nakashima H, Imagawa T, Uehara M, Tsubota K. D-beta-hydroxybutyrate protects against corneal epithelial disorders in a rat dry eye model with jogging board. *Invest Ophthalmol Vis Sci* 2005;46:2379-87.
17. Nakamura S, Shibuya M, Nakashima H, Hisamura R, Masuda N, Imagawa T, et al. Involvement of oxidative stress on corneal epithelial alterations in a blink-suppressed dry eye. *Invest Ophthalmol Vis Sci* 2007;48:1552-8.
18. Lemp MA, Crews LA, Bron AJ, Foulks GN, Sullivan BD. Distribution of aqueous-deficient and evaporative dry eye in a clinic-based patient cohort: A retrospective study. *Cornea* 2012;31:472-8.
19. Nagaoka M, Maeda T, Chatani M, Handa K, Yamakawa T, Kiyohara S, et al. A Delphinidin-enriched Maqui berry extract improves bone metabolism and protects against bone loss in osteopenic mouse models. *Antioxidants (Basel)* 2019;8:386.
20. Binshtok AM, Wang H, Zimmermann K, Amaya F, Vardeh D, Shi L, et al. Nociceptors are interleukin-1beta sensors. *J Neurosci* 2008;28:14062-73.
21. Kim CF, Moalem-Taylor G. Interleukin-17 contributes to neuroinflammation and neuropathic pain following peripheral nerve injury in mice. *J Pain* 2011;12:370-83.
22. Milligan ED, Penzkover KR, Soderquist RG, Mahoney MJ. Spinal interleukin-10 therapy to treat peripheral neuropathic pain. *Neuromodulation* 2012;15:520-6; discussion 526.



British Society for Refractive Surgery

Lenticule Extraction: Will LASIK cease to exist?

BSRS Annual Meeting in Oxford
Saturday 8th July - Sunday 9th July 2023



Charles McGhee lecture by Professor Jod Mehta

Distinguished Professor of Clinical Innovation, Head of the Corneal Service, Head of the Tissue Engineering and Stem Cell Group, Professor of DUKE-NUS Graduate Medical School

Singapore National Eye Centre & Singapore Eye Research Institute



Other topics at the meeting

- Different lenticule extraction platforms (CLEAR, SMILE, Elita, Smartsight)
- Presbyopic LASIK
- Presbyopic phakic IOL
- New EDOF IOLs
- Keratoconus management
- Biometry in irregular corneas



Introducing

FINEVISION HP

Trifocal Hydrophobic IOL



FINE technology:

The Gold Standard with 10 years follow-up

106th Oxford Ophthalmological Congress

The 106th Congress
will be held on
3rd, 4th & 5th July
2023



The symposia will feature:

Masters Symposium: Vitreo Retinal surgery -
Perennial problems; new solutions.

Why are you missing out? WAYMO!
Myopia: Prevalence, prevention, lens & retina
Oncology, oculoplastics & ocular pathology.

Eyes are not islands: What ophthalmologists need to
know about systemic eye disease.

The Doyne Lecture will be presented by
Prof. Gullapalli N Rao, Prasad Eye Institute.

Supported by an innovative industry exhibition.

Register at www.ooc.uk.com



EvoTears®

Allow your patients worries to evaporate, not their tears.

The first **water-free** drops in the management of evaporative dry eye and MGD.



RELIEVES symptoms of Evaporative Dry Eye Disease



REPLACES the outer lipid layer of the tear film creating an outer shield



REDUCES evaporation of the tear film



Complete Lipid Replacement



Preservative, Phosphate and Water Free



Long Lasting Relief



6 Months Use from Opening



Small Drops. Big Benefits